

Case 2

81F

Rt. IC-Pcom AN

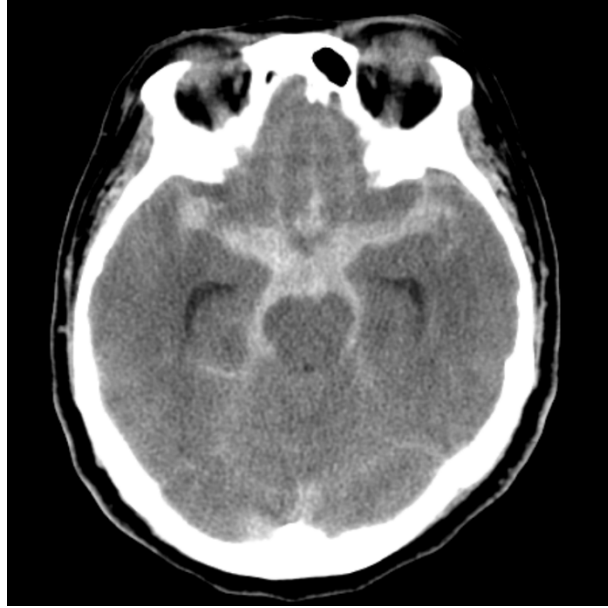
(previously ruptured & coiled, recurrence)

Case 2

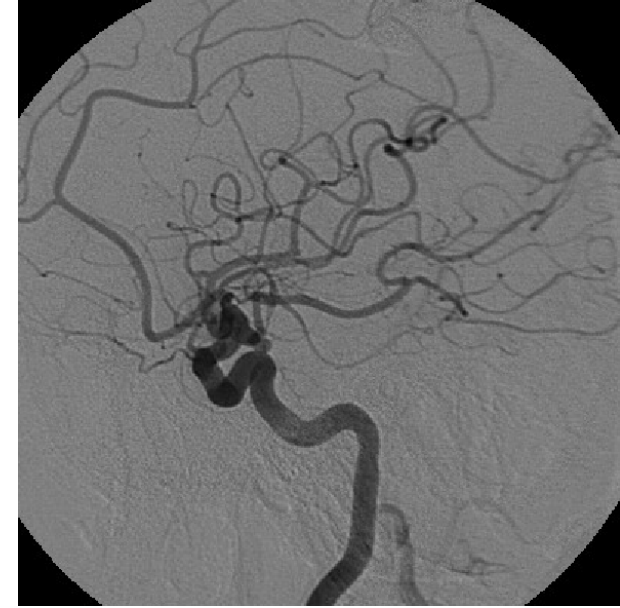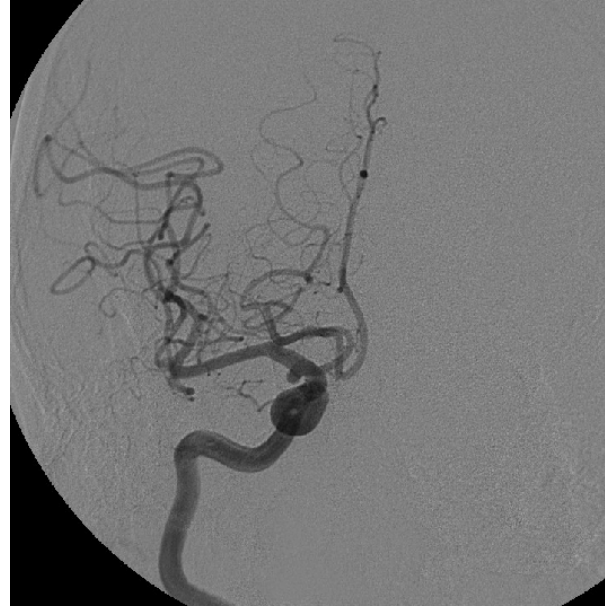81F

現病歴	17年前(64歳)くも膜下出血で当院に入院。破裂右IC-Pcom瘤に対しcoilingを施行され、mRS 0で退院。経過良好で、6年前にF/Uが途絶えていた。1年ほど前から右眼瞼下垂をきたし、近医を受診。MRIで動脈瘤の再発を指摘され、当院に紹介された。
既往歴	高血圧症、脂質異常症
内服薬	アムロジピン5mg、アジルサルタン40mg、エサキセレノン2.5mg、フルイトラン1mg、アスピリン100mg、ファモチジン20mg、ブロチゾラム0.25mg
生活歴	特記すべき事項なし
現症	右動眼神経麻痺(軽度眼瞼下垂・複視) その他には明らかな神経学的異常はない

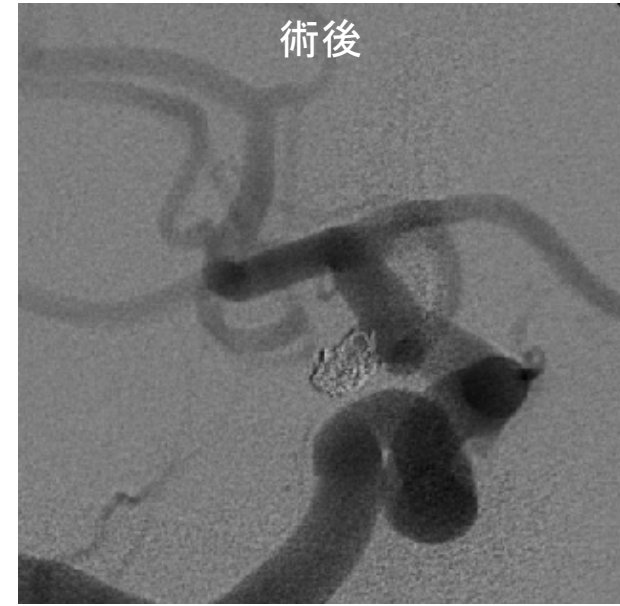
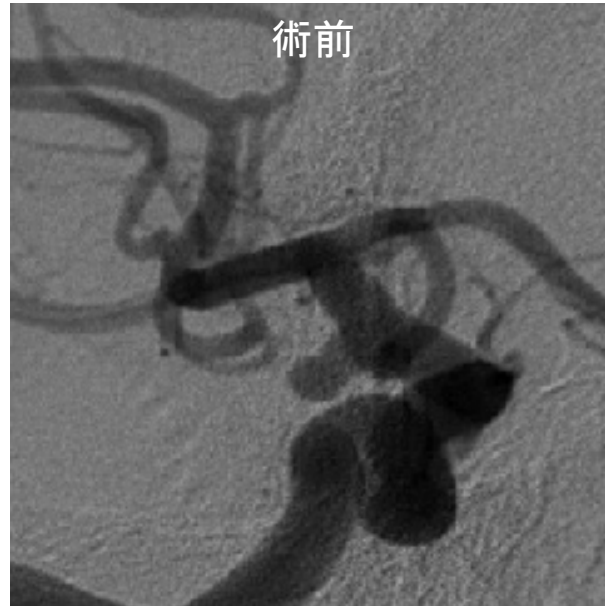来院時CT



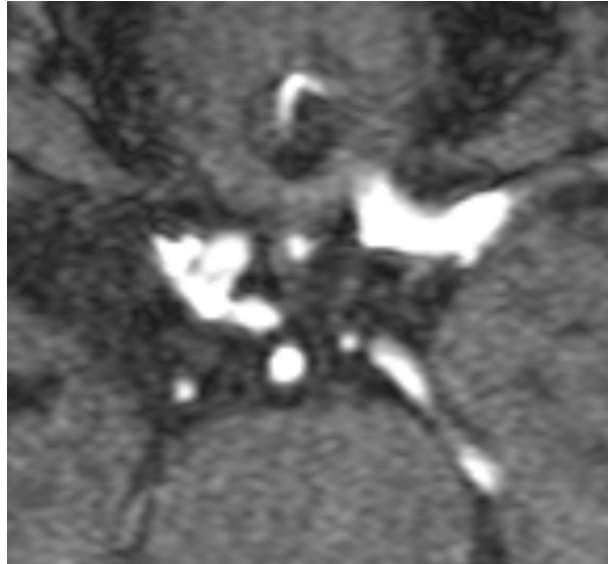初回治療時 Rt. ICAG



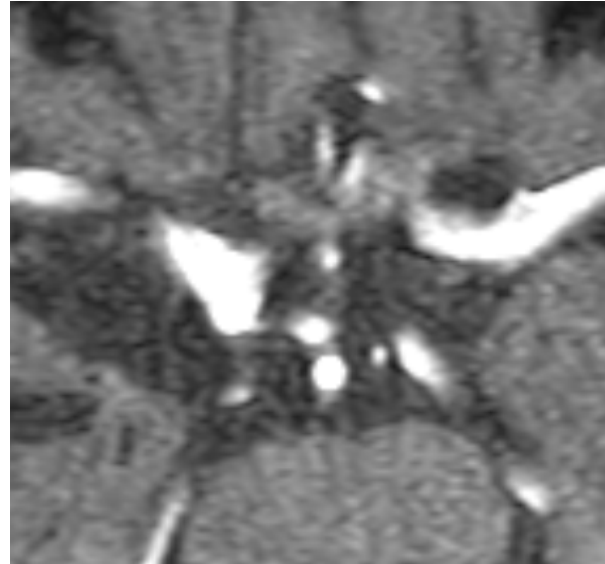
コイル塞栓術



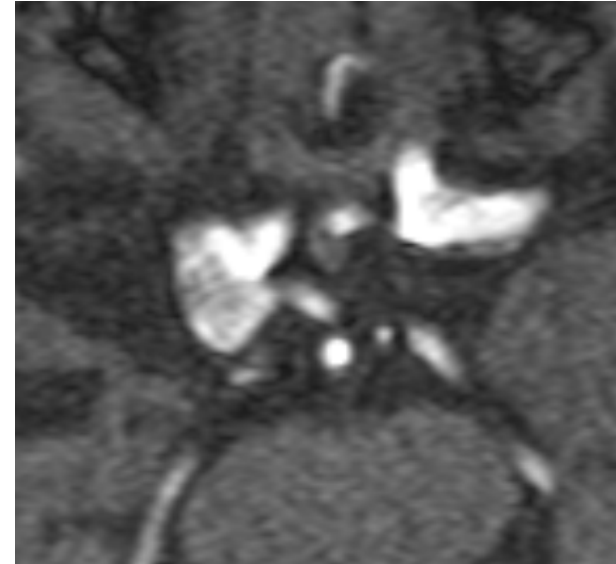Follow-up TOF-MRA



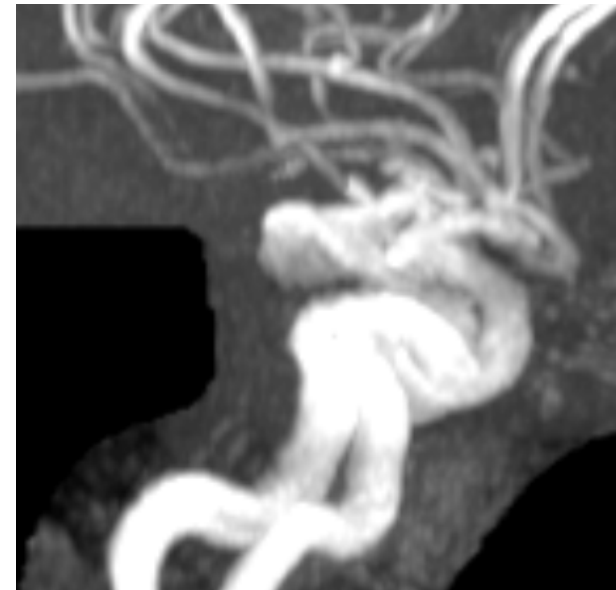
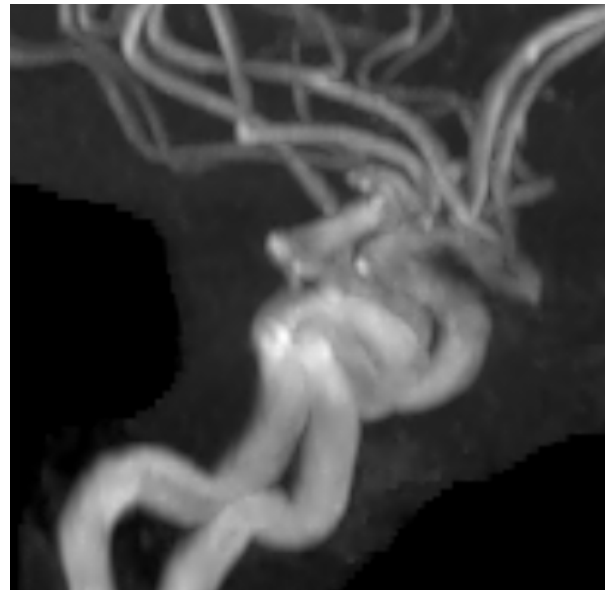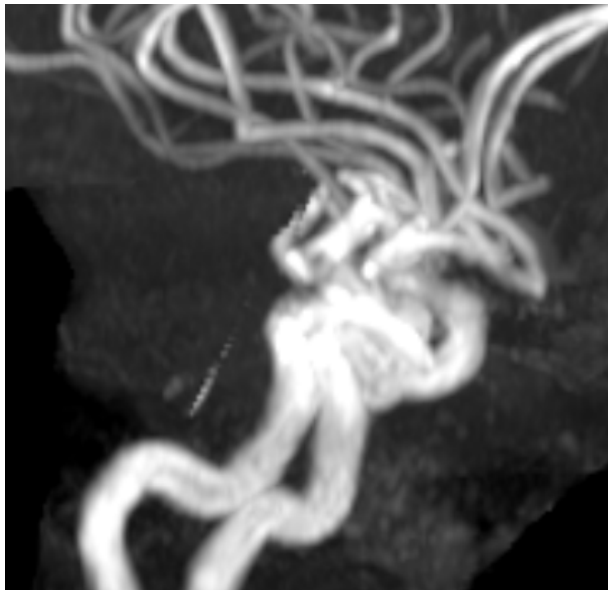
術2年後



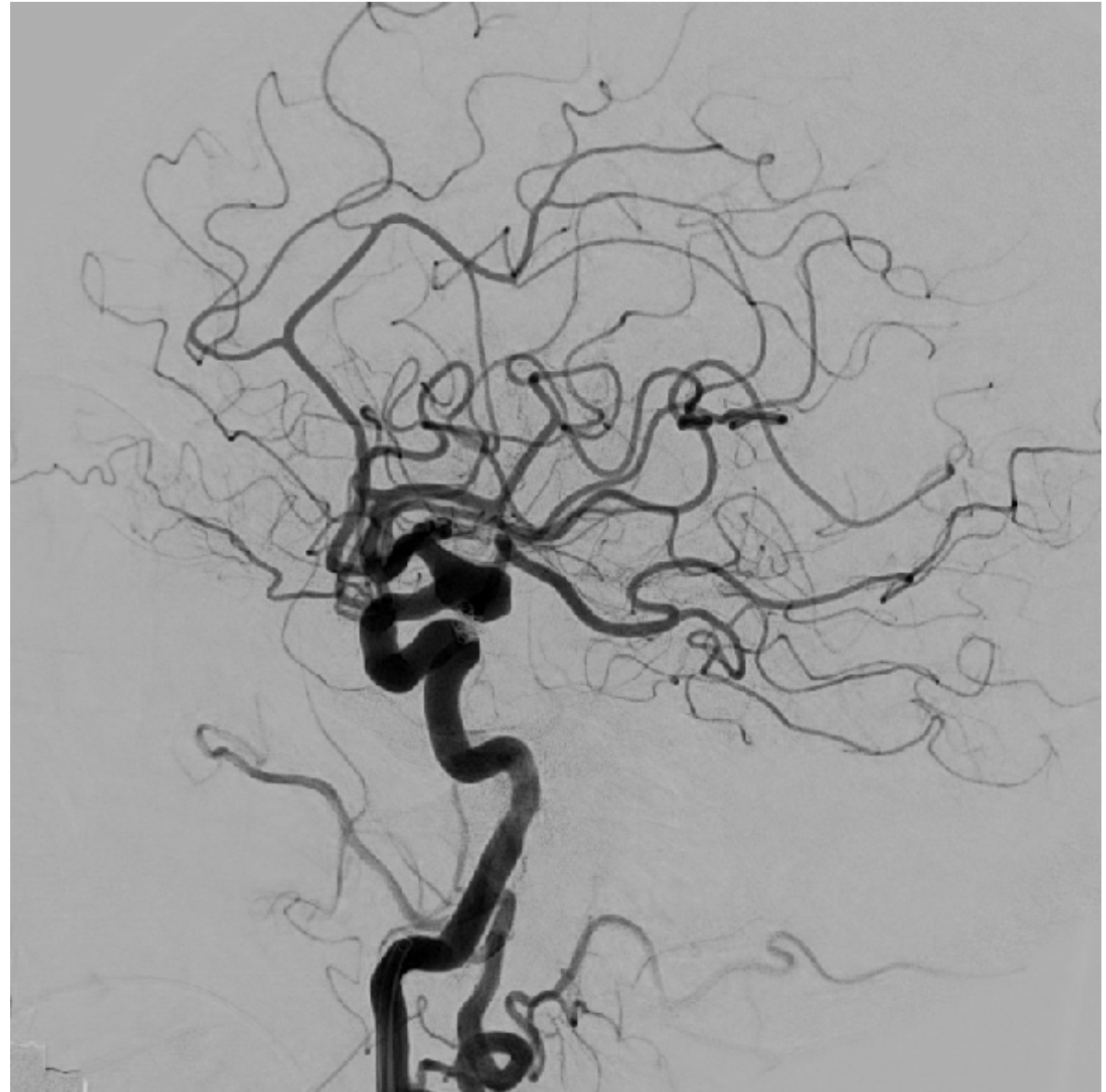
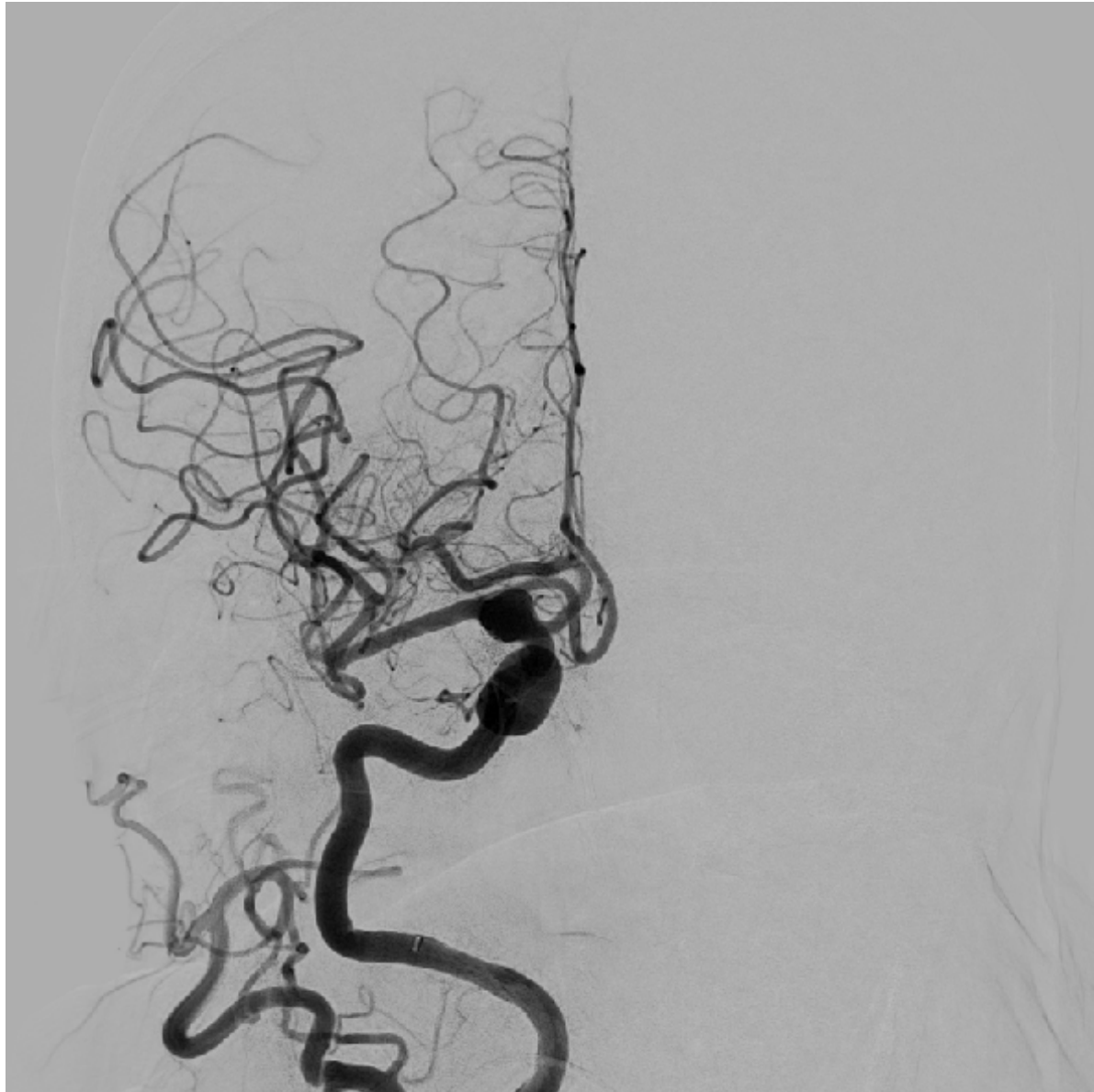
術11年後



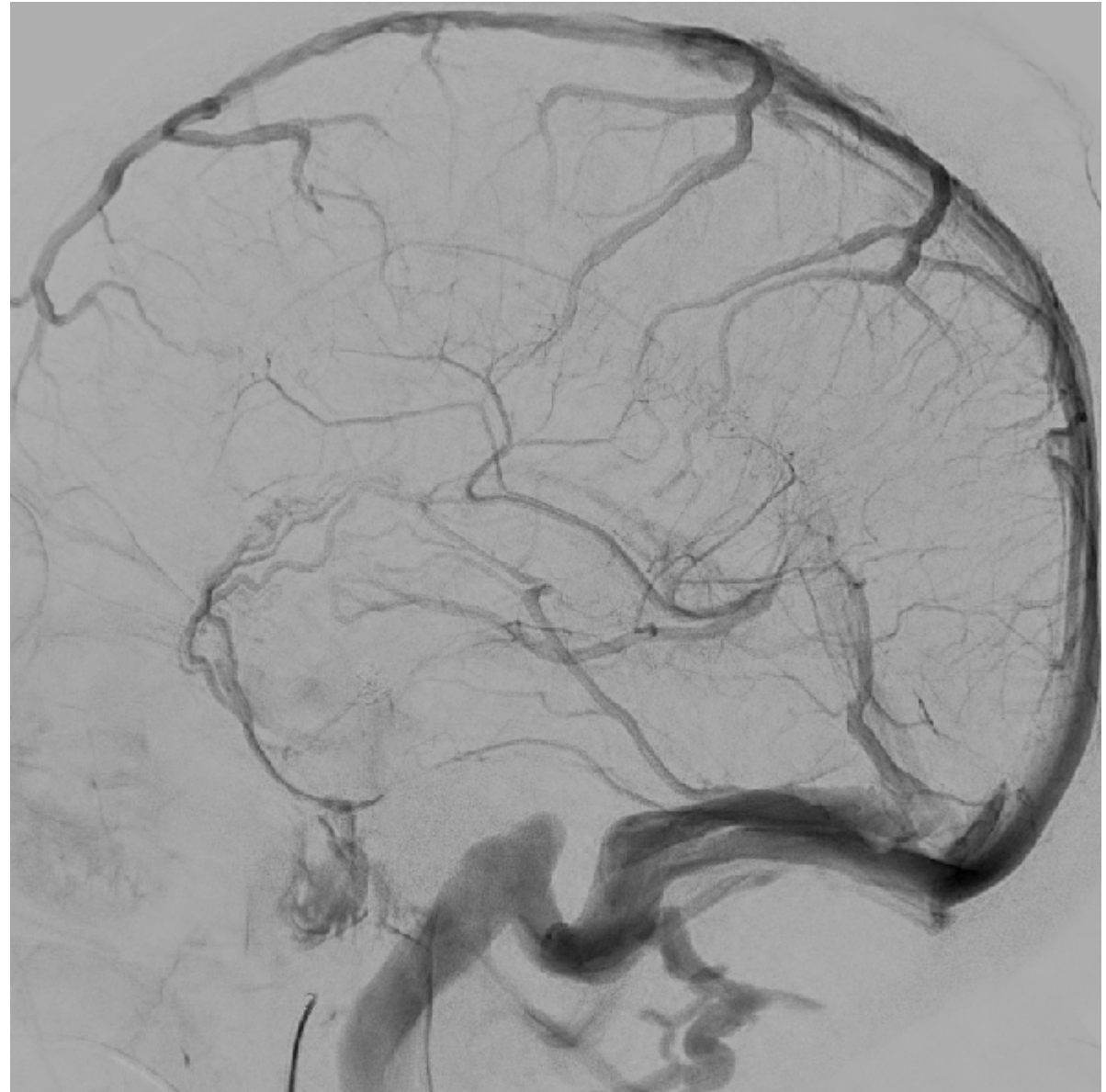
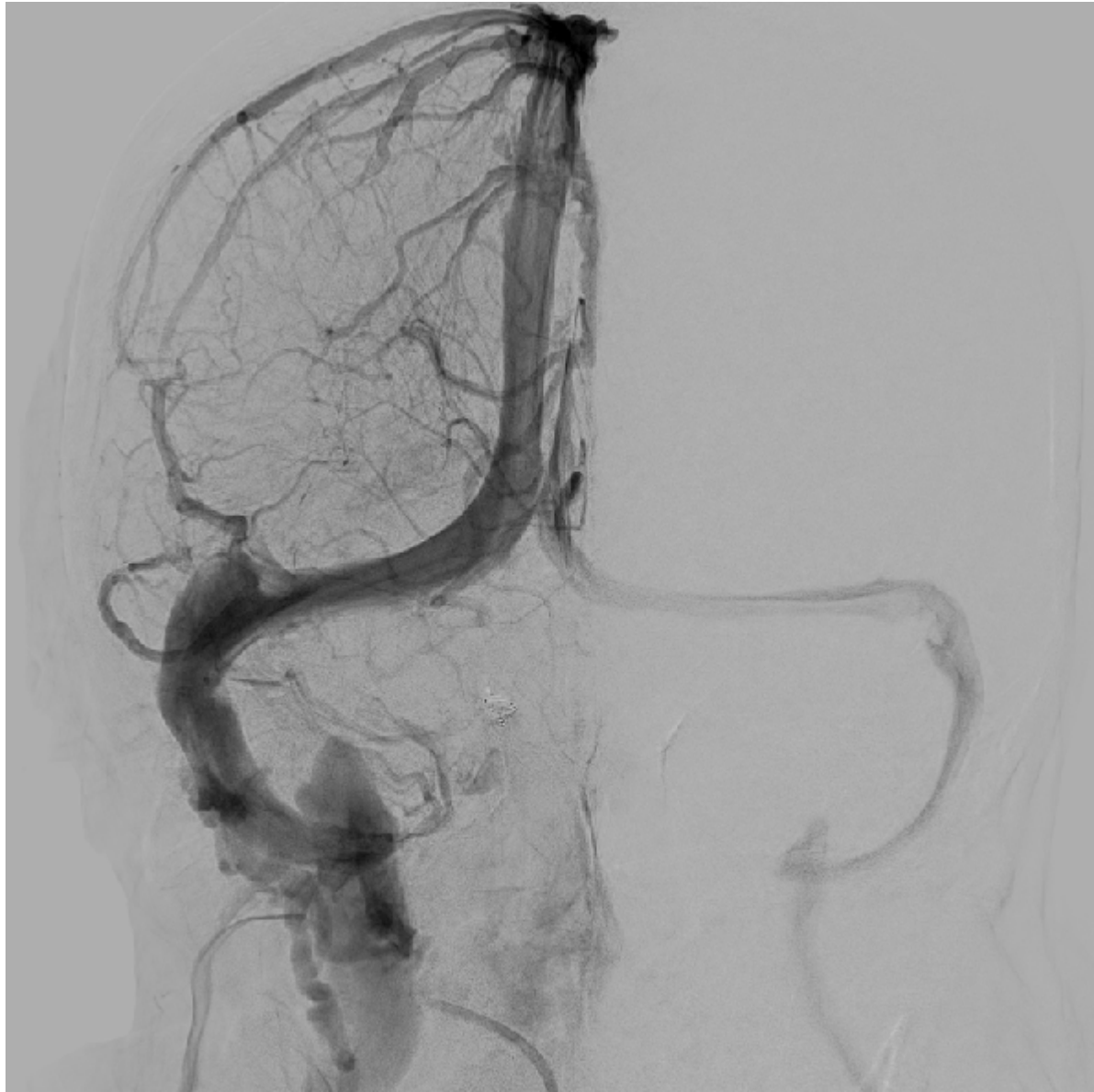術17年後



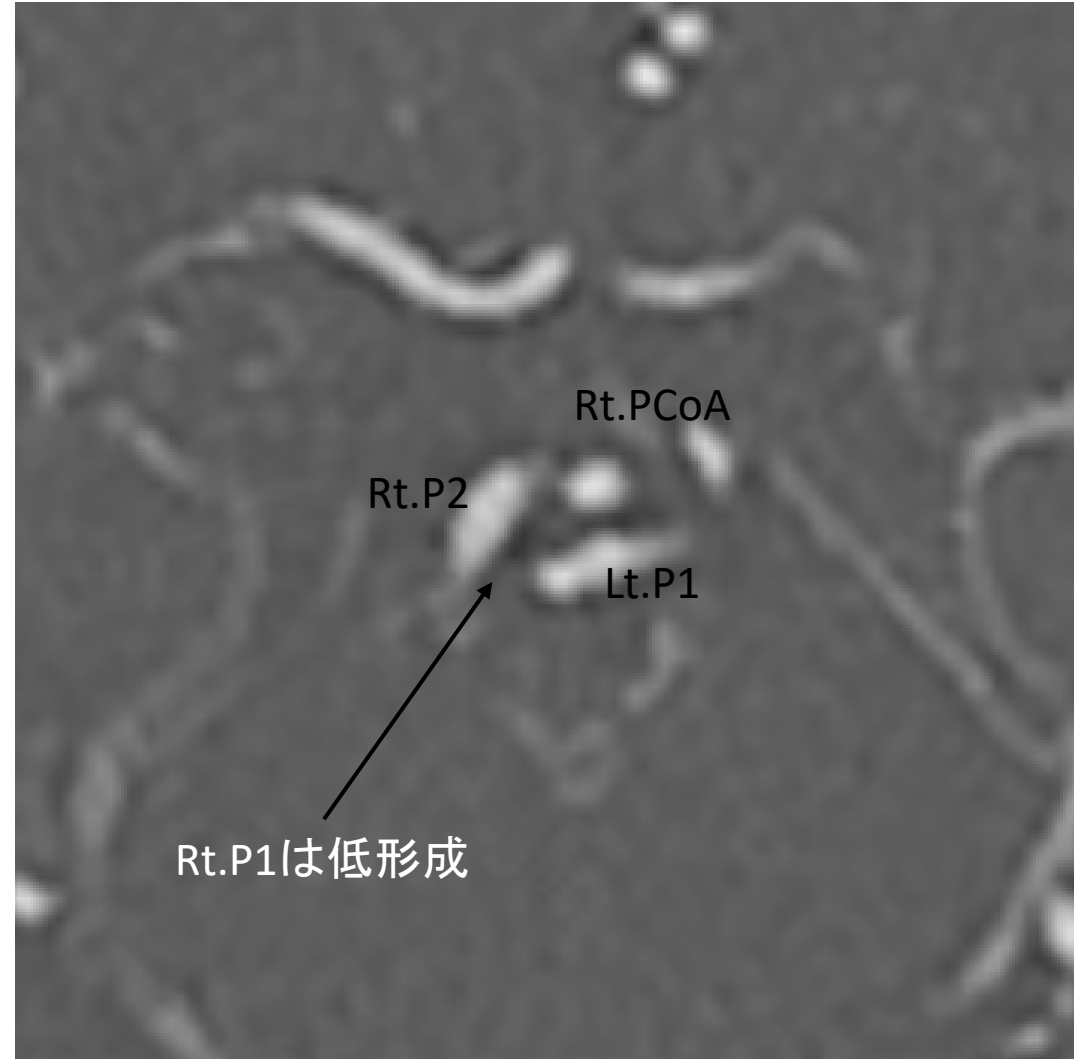
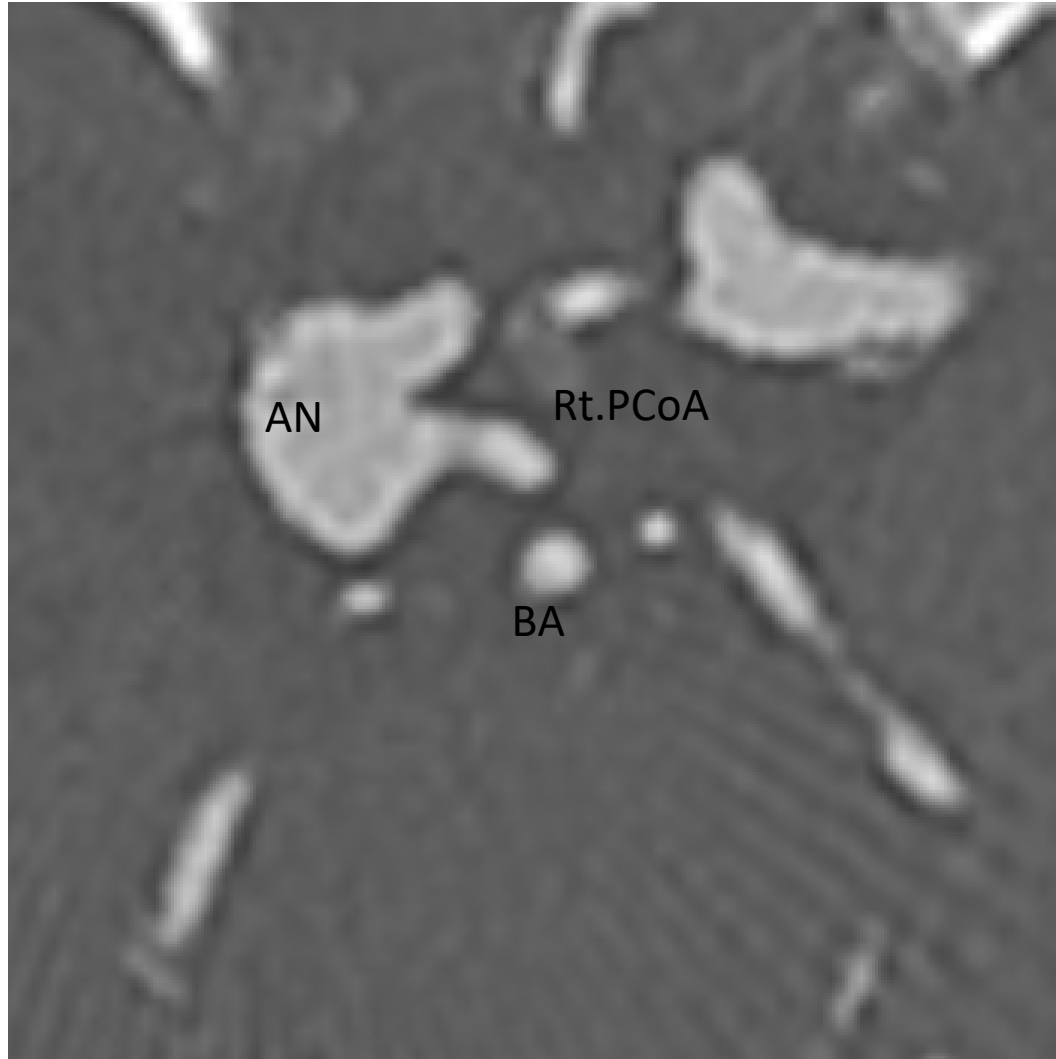
Rt. ICAG



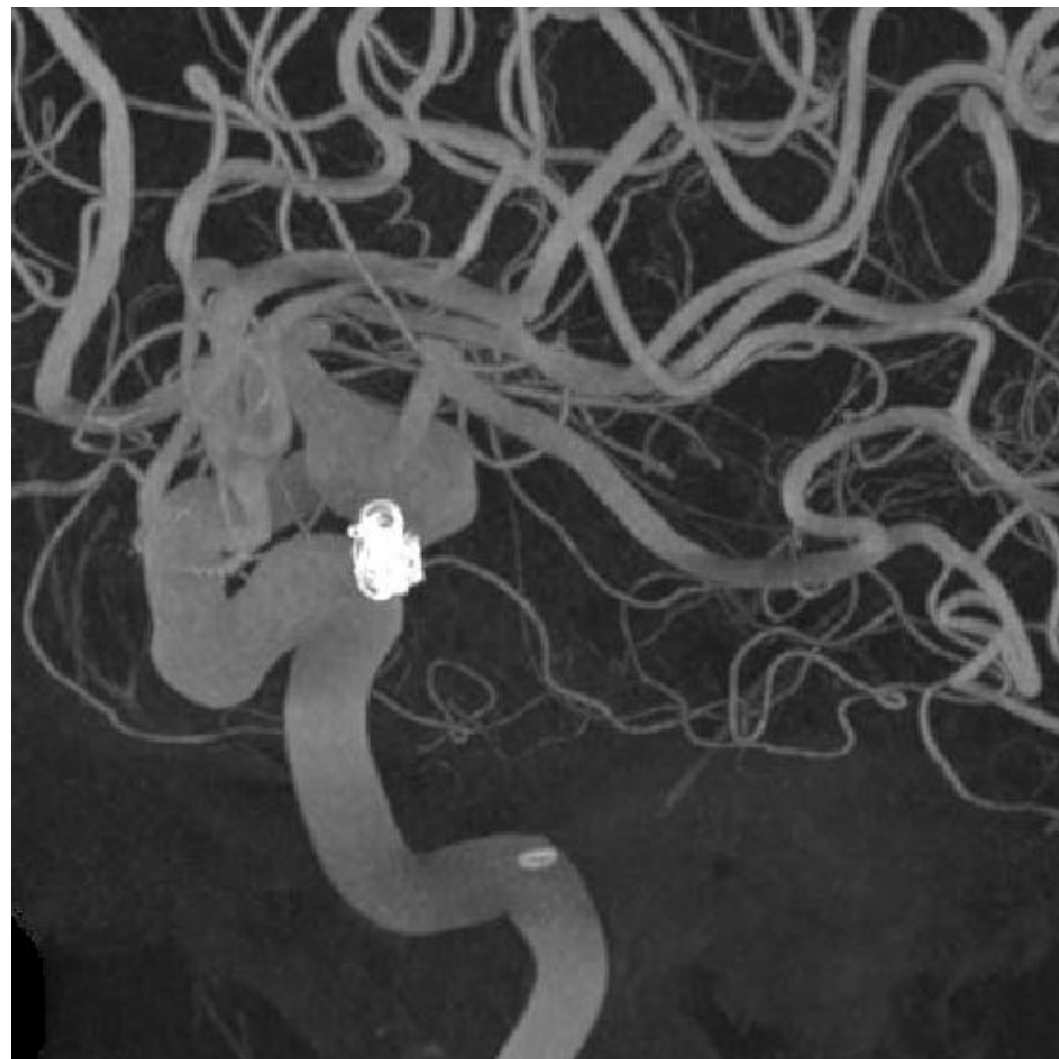
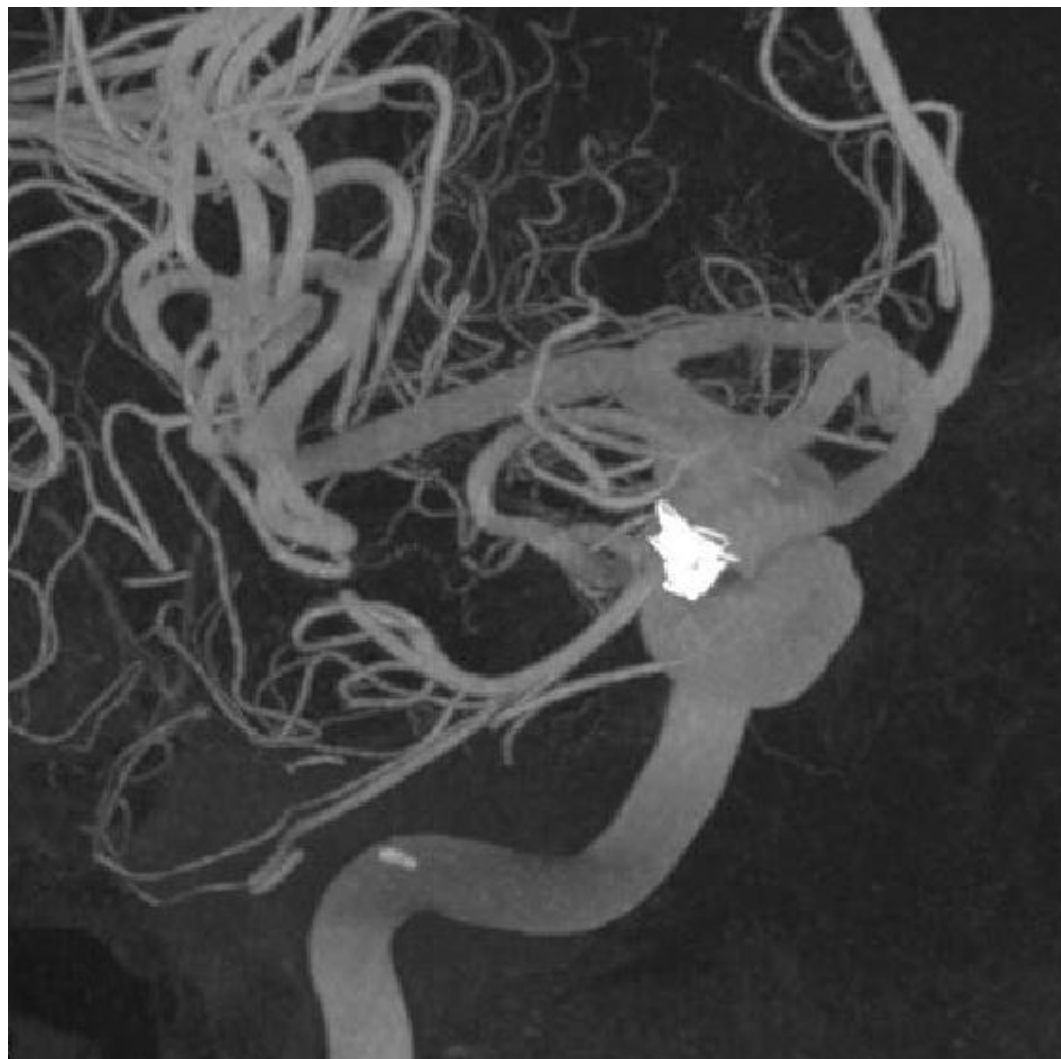
Rt. ICAG



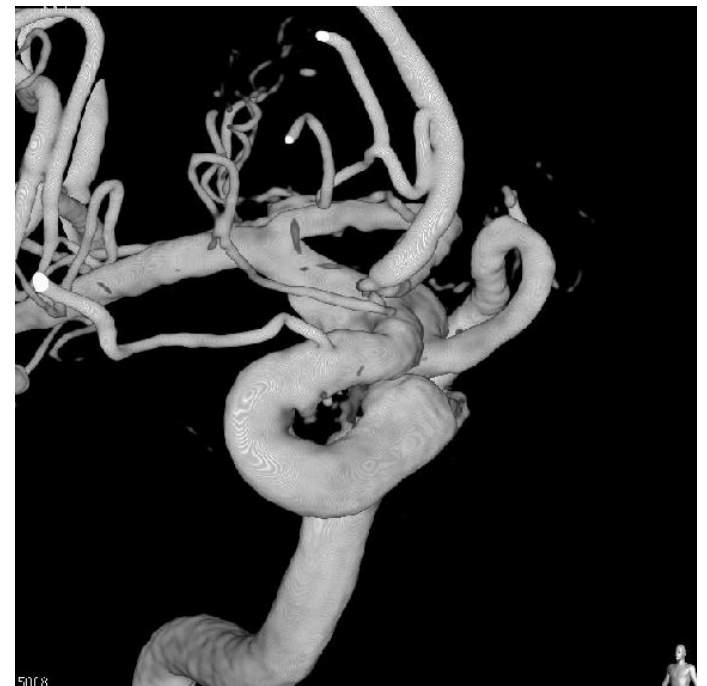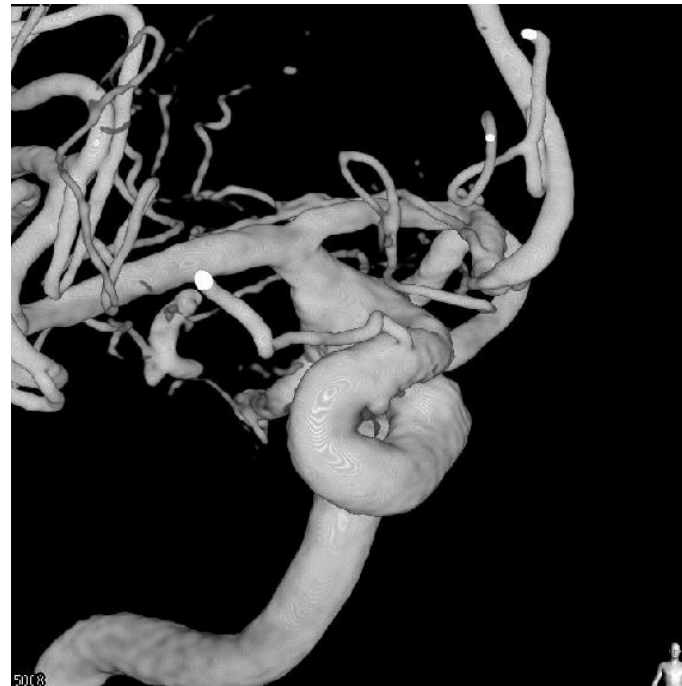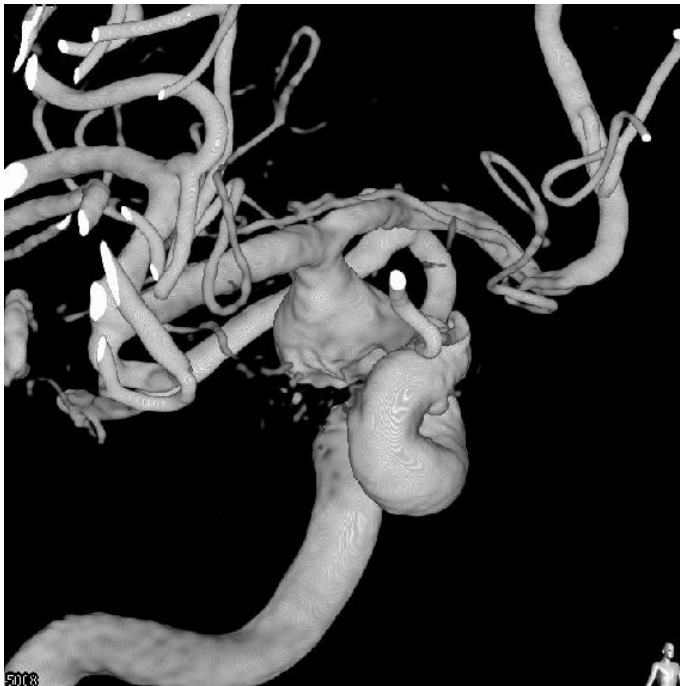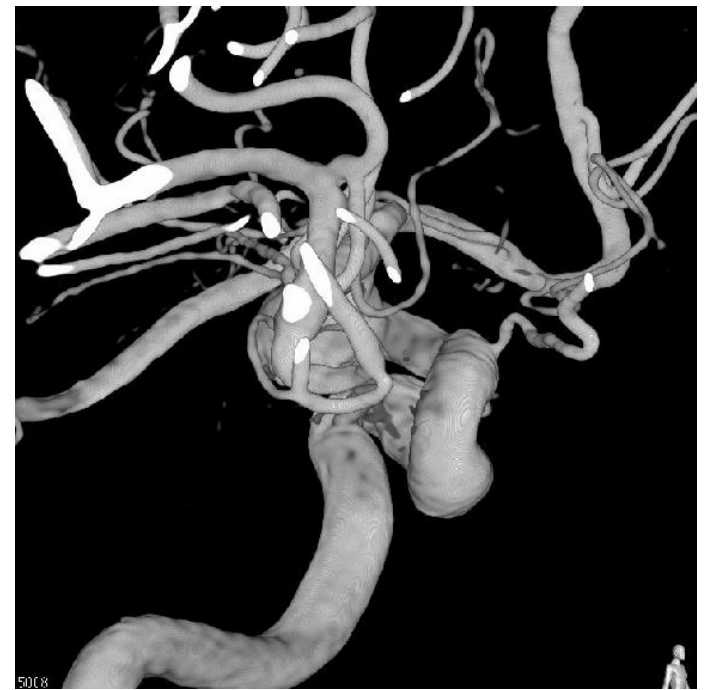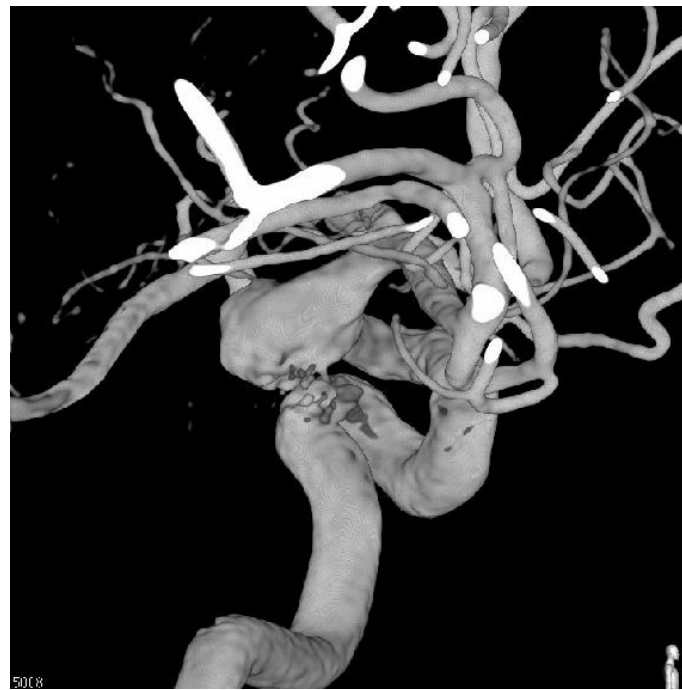CTA



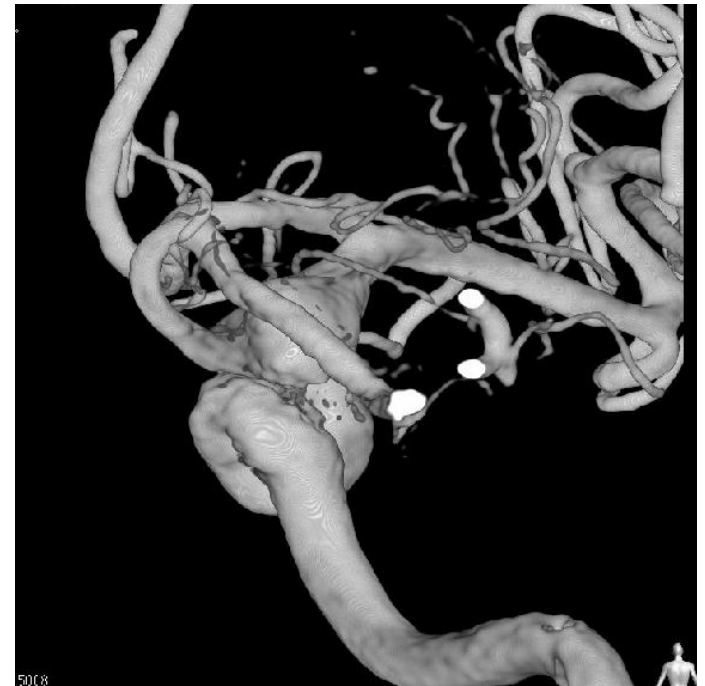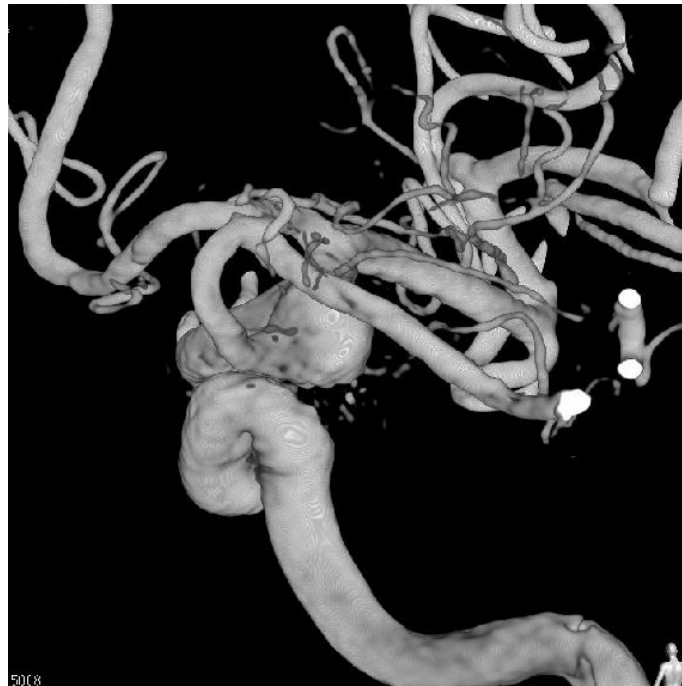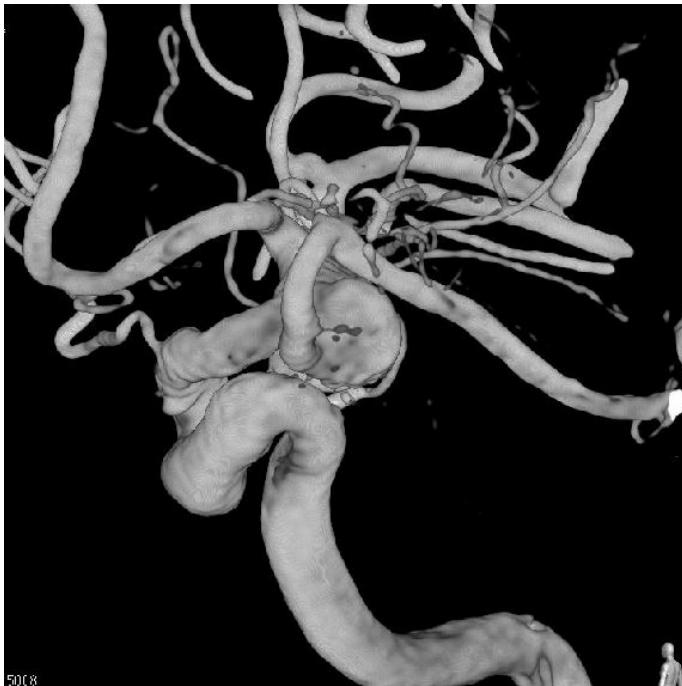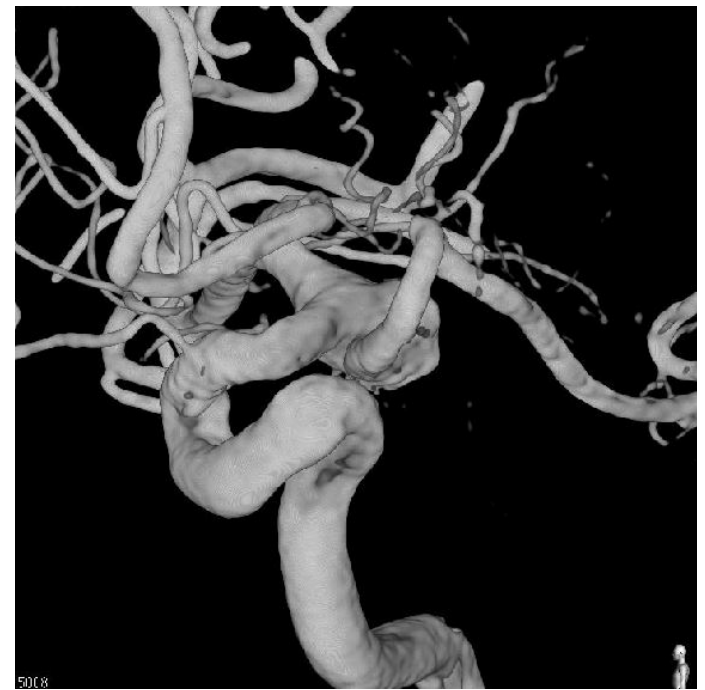
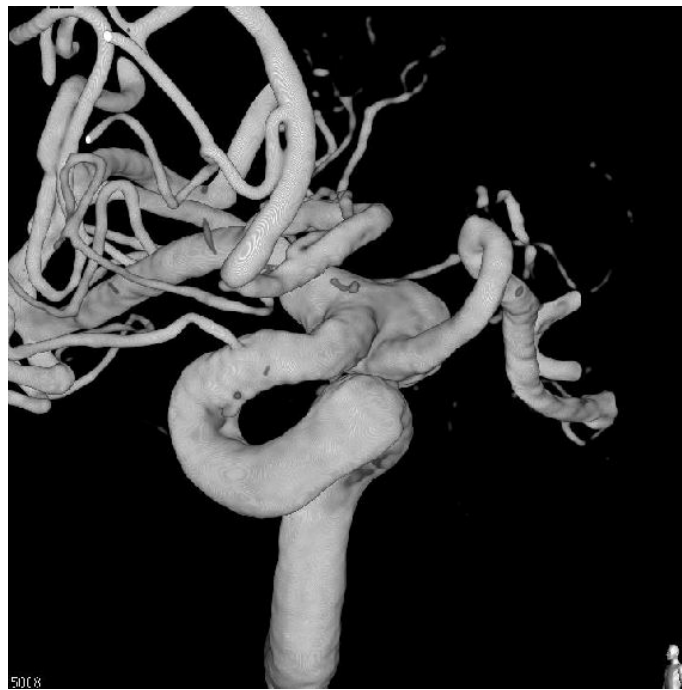
Rt. ICA 3D-RA



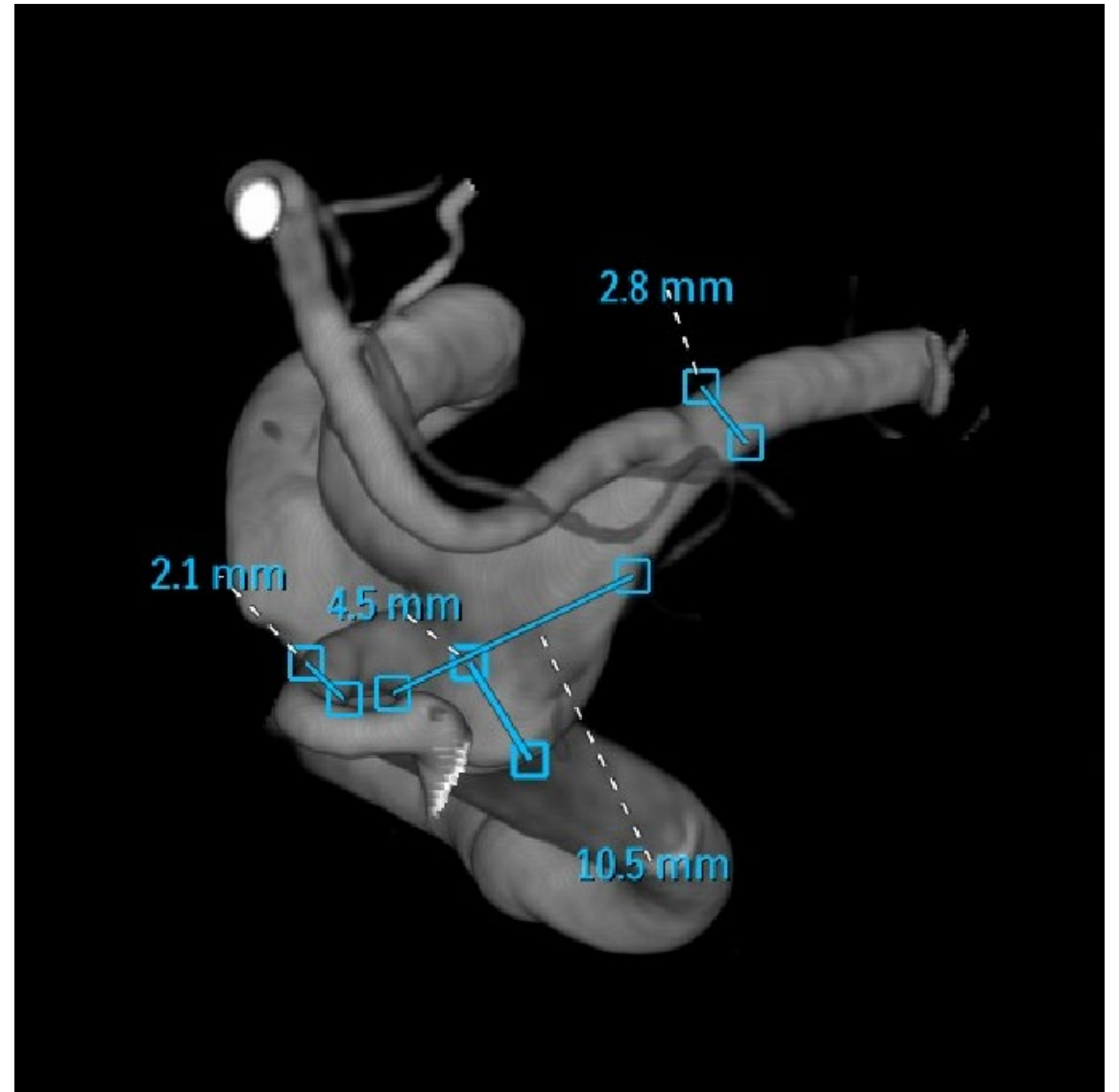
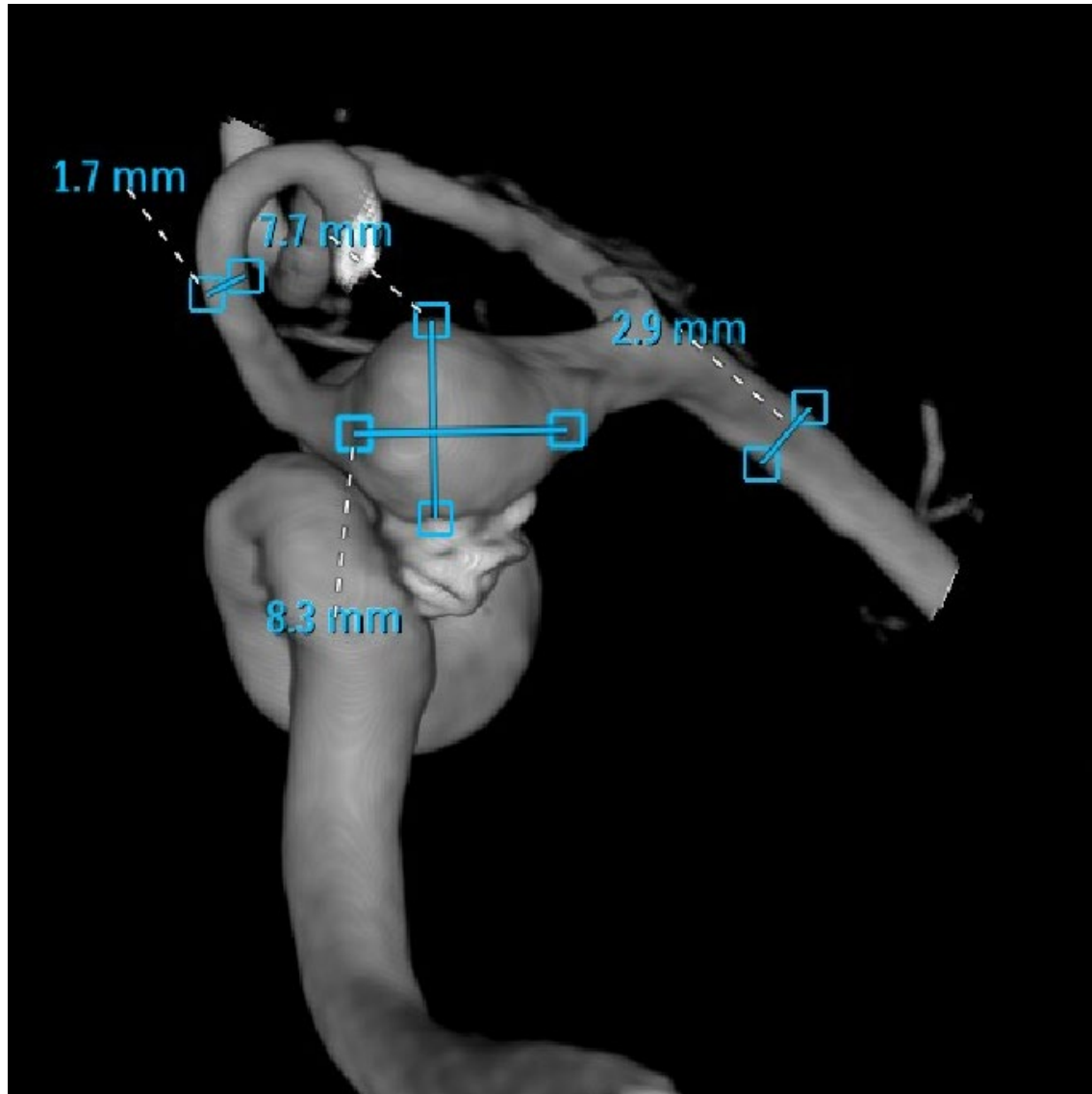
Rt. ICA 3D-RA



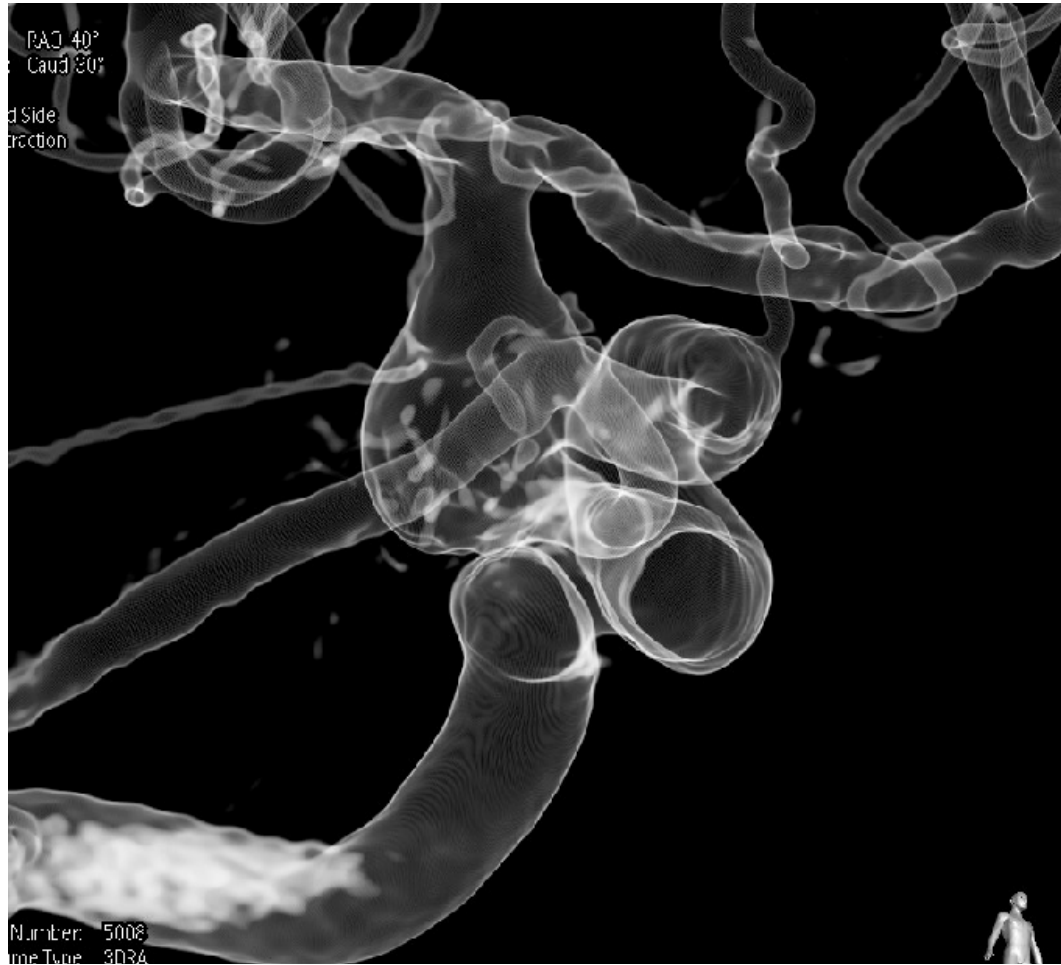
Rt. ICA 3D-RA



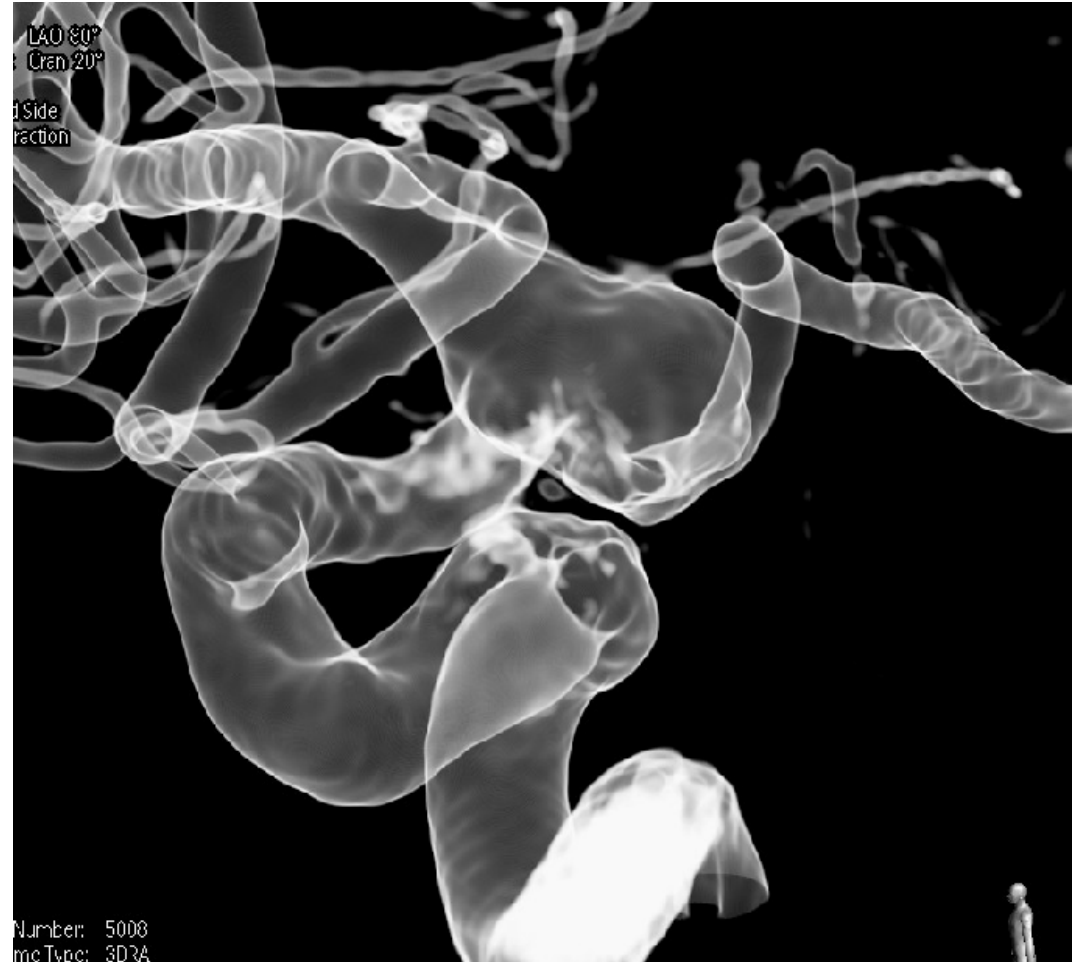
Rt. ICA 3D-RA



Rt. ICA 3D-RA Working angle

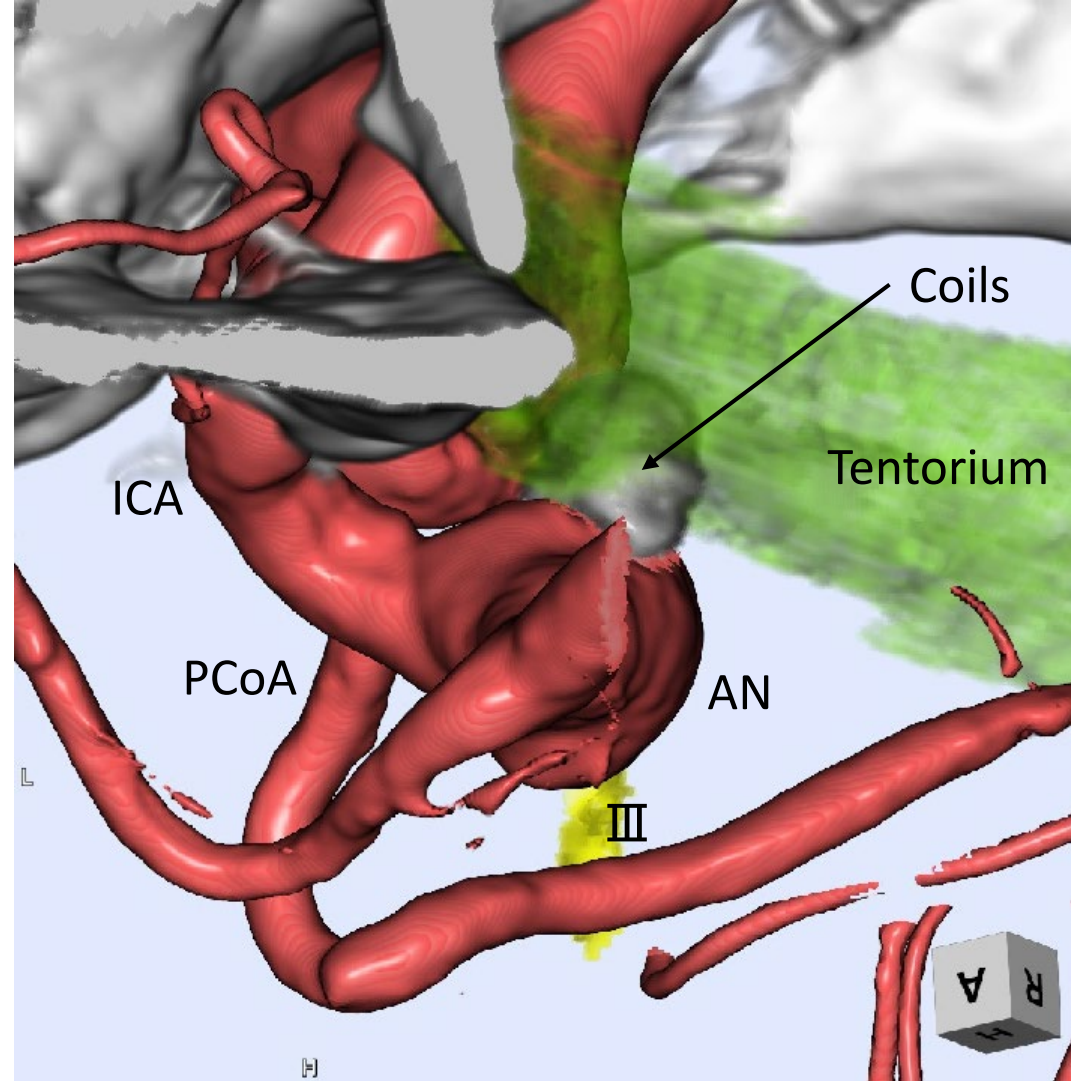


RAO40 / CAU30

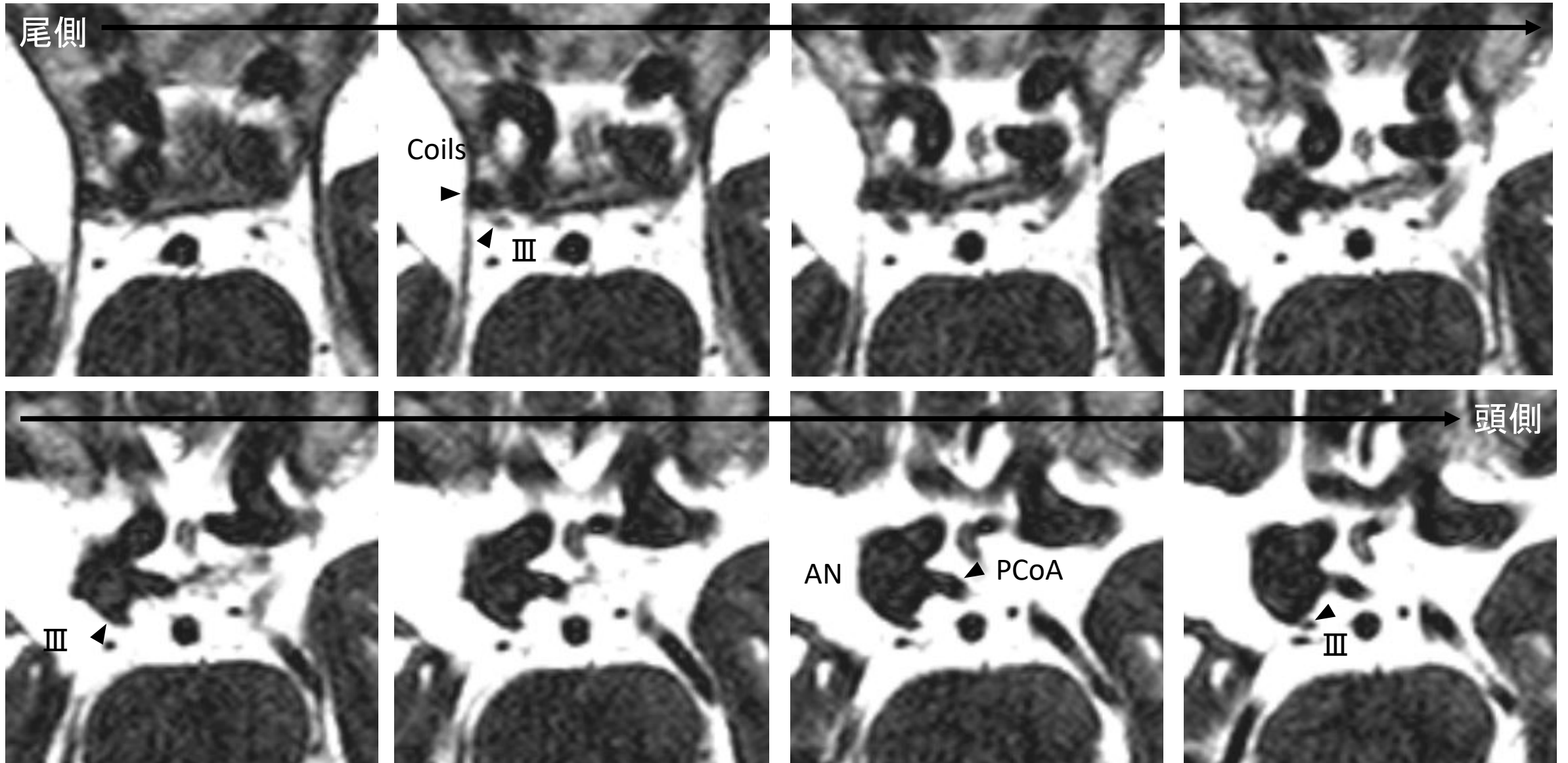


RAO100 / CAU20

3D images fusion (CT, MRI, and 3D-RA)



Heavily T2WI



Case 2 summary

- ✓ 破裂IC-Pcom動脈瘤、coiling 17年後に再発(動眼神経麻痺)
- ✓ 瘤は増大しており、wide neck
- ✓ Fetal type Pcom incorporated

To be discussed...

- ✓ 治療は？ 直達手術？ 血管内治療？
- ✓ 血管内治療の場合
 - ①Double catheter ②Balloon assist ③Stent assist (single)
 - ④Stent assist (multiple) ⑤Flow diverter ⑥その他