

## 症例6

# 69y.F 未破裂右内頸動脈C1部動脈瘤

## 【既往歴】

慢性関節リウマチ、高血圧症、糖尿病  
両側緑内障、右糖尿病性網膜症・眼底出血(OP)

## 【内服薬】

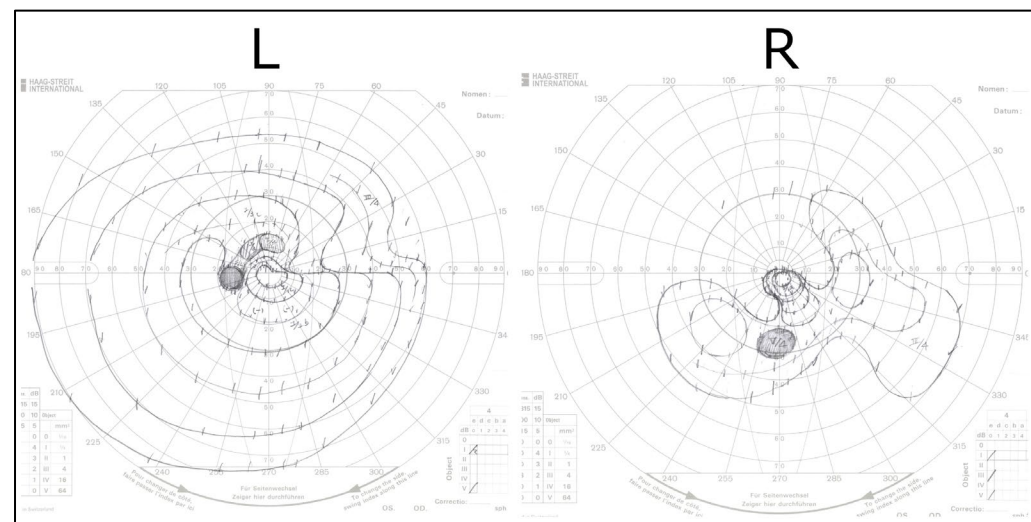
メトトレキサート、アムロジピン、バルサルタン

## 【現病歴】

頭痛の精査で右内頸動脈瘤(10.2mm)を発見された

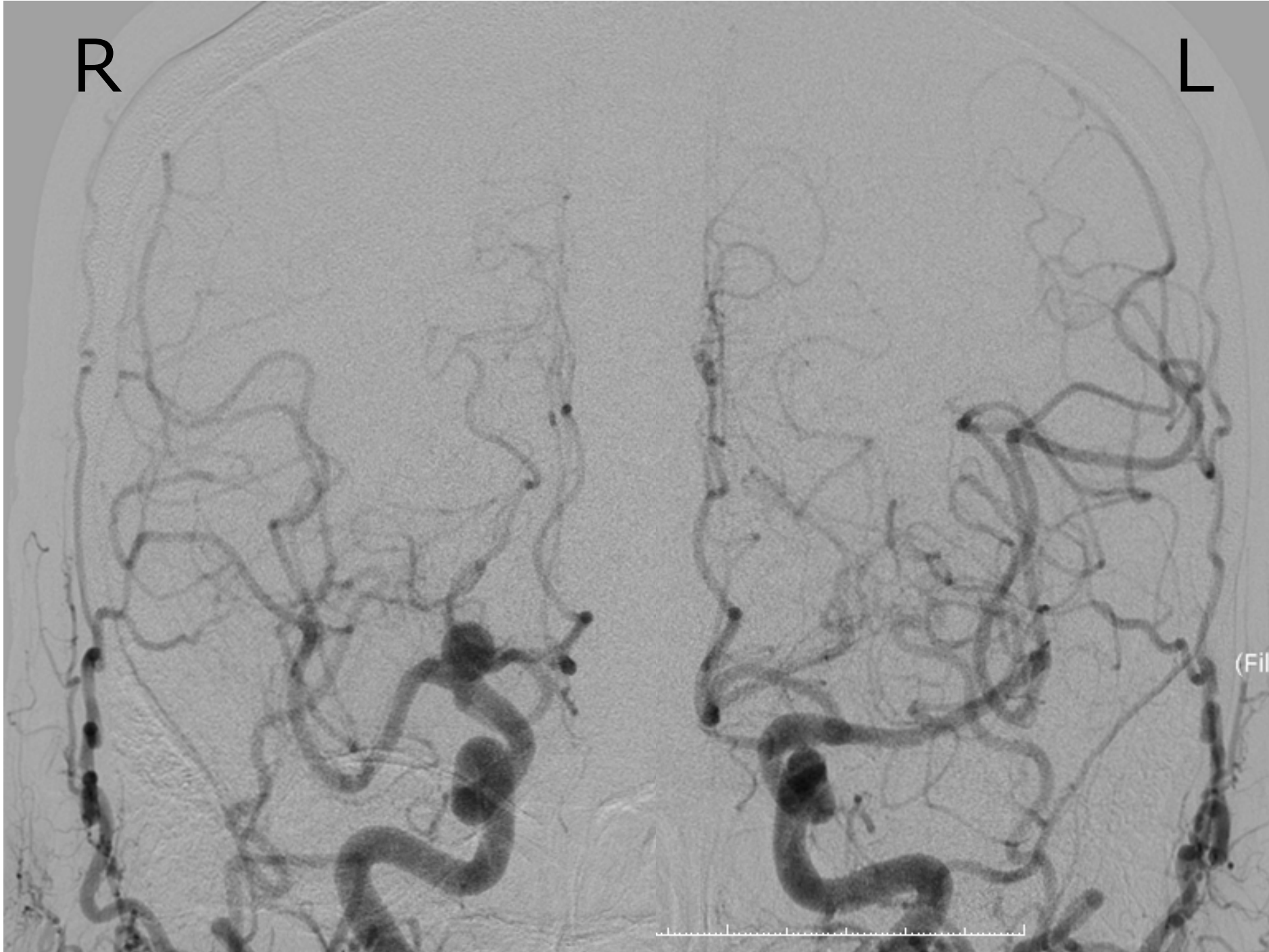## 【神経学的所見】

両側視野障害



R

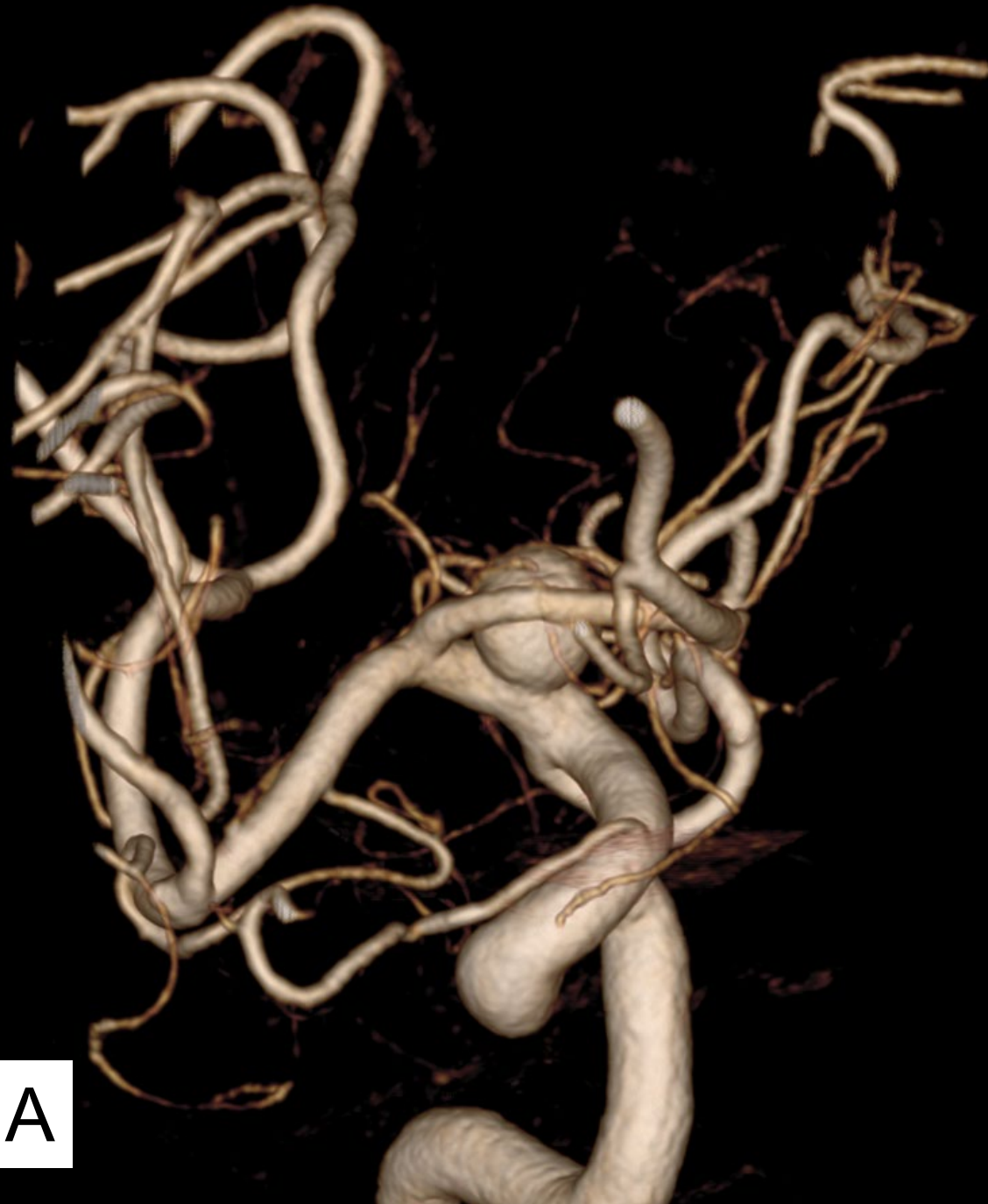L



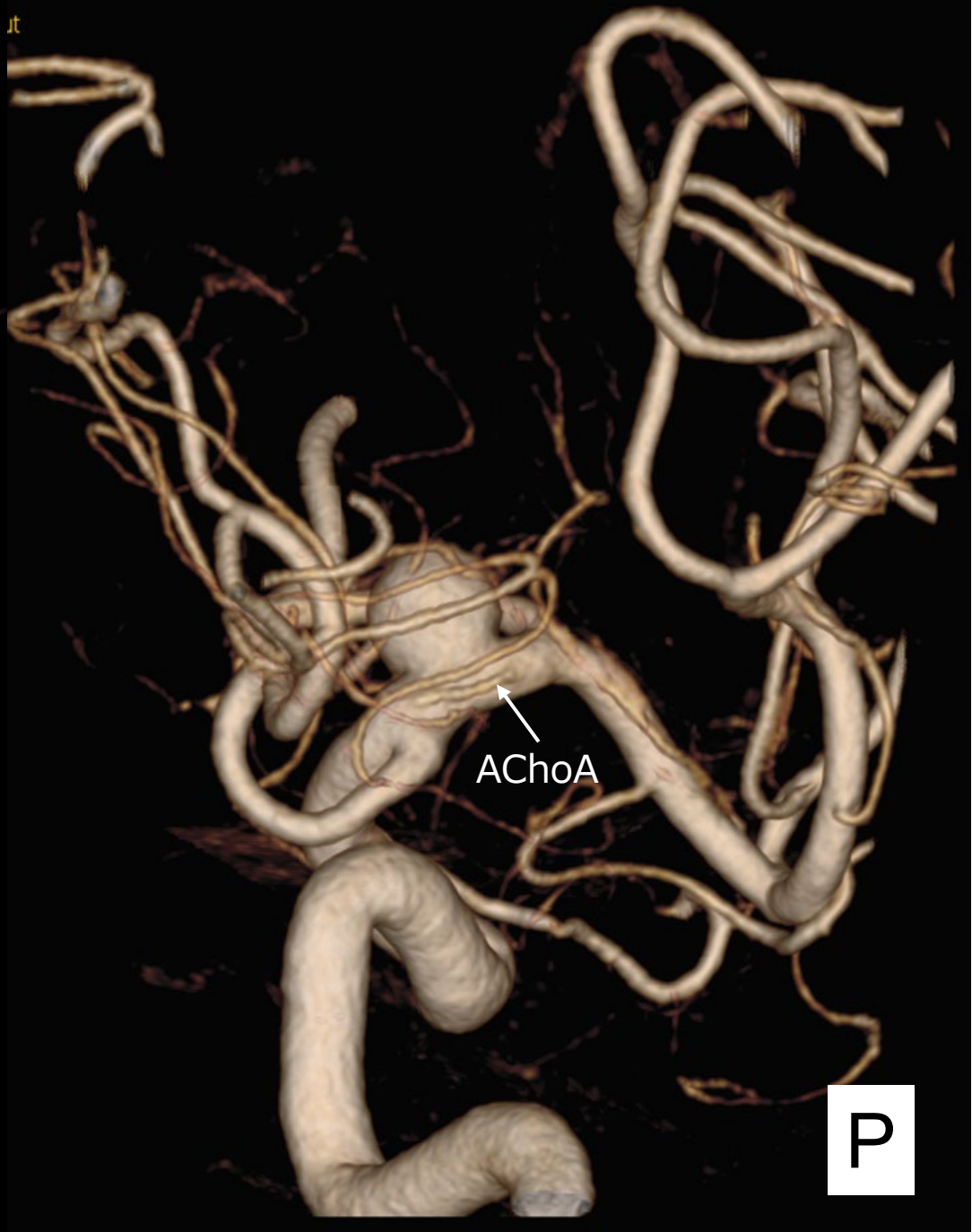(Fil

t

it



A

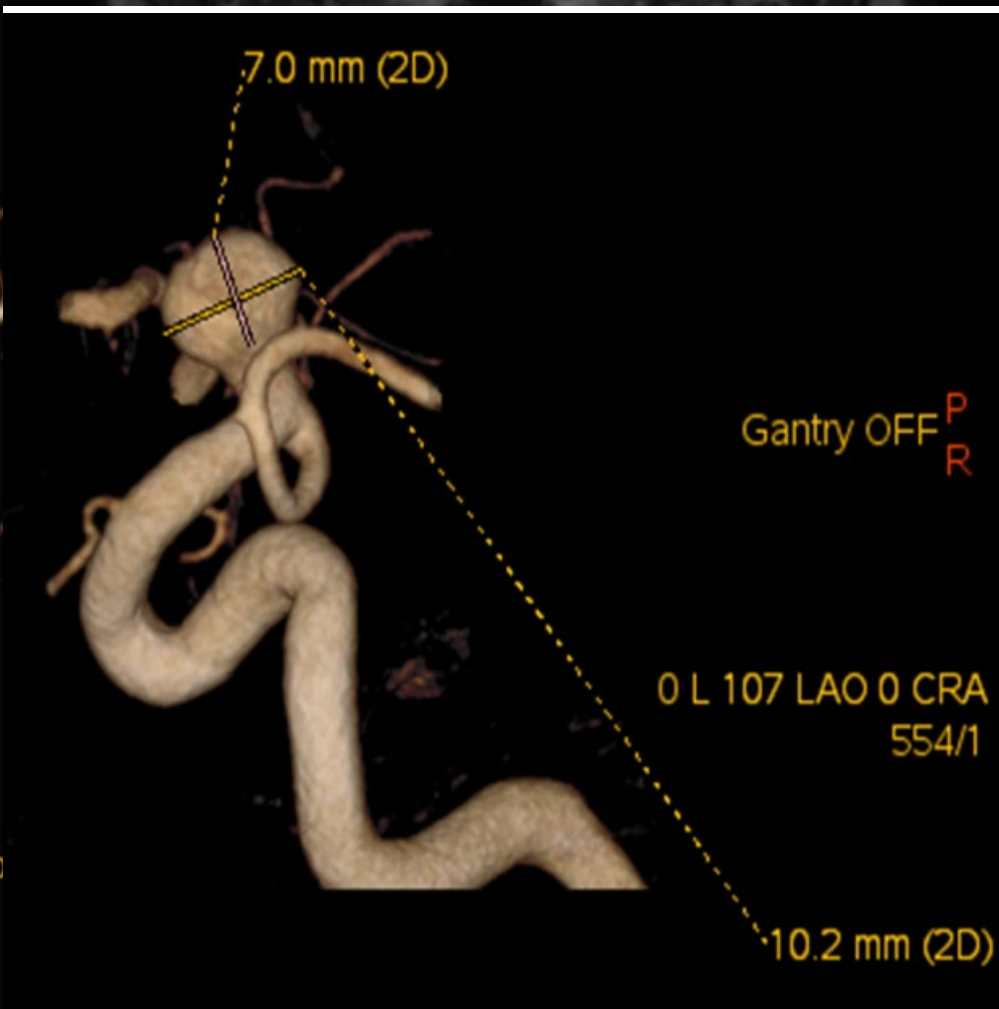
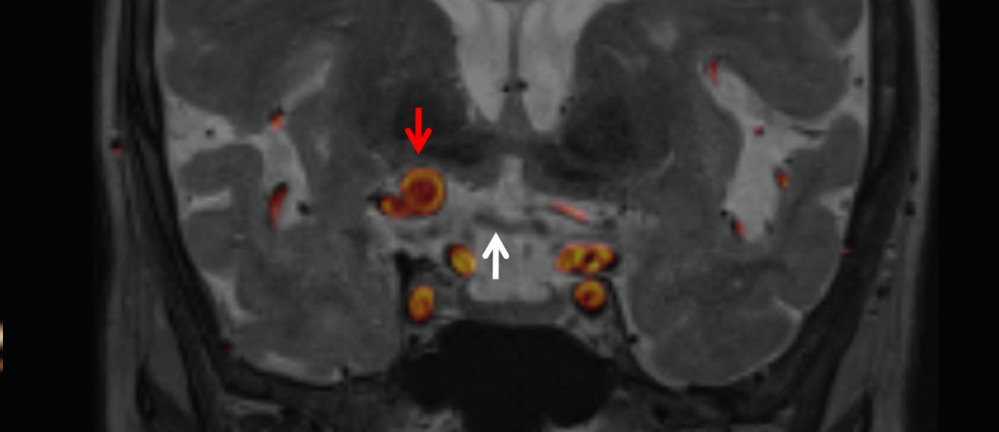
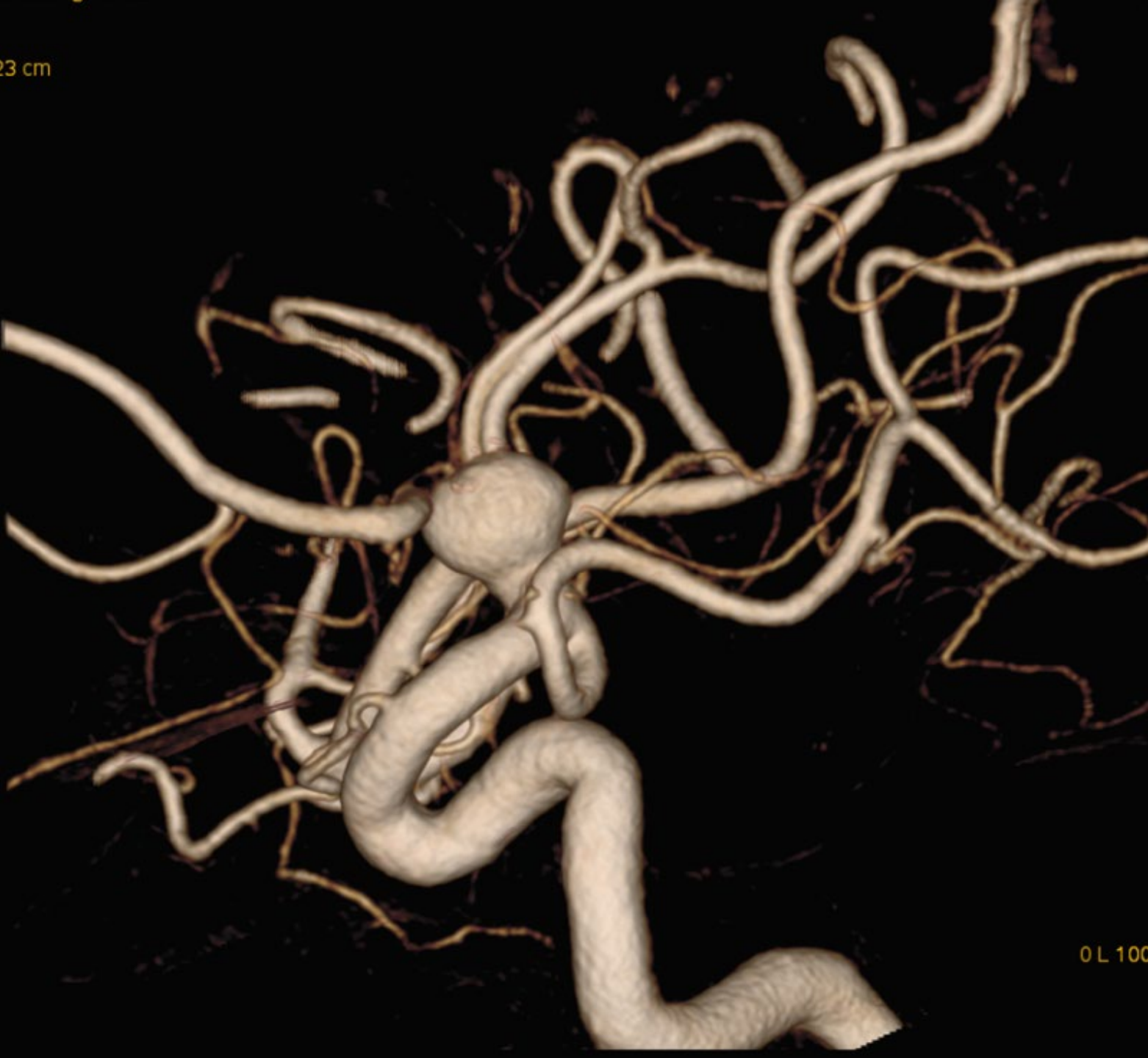
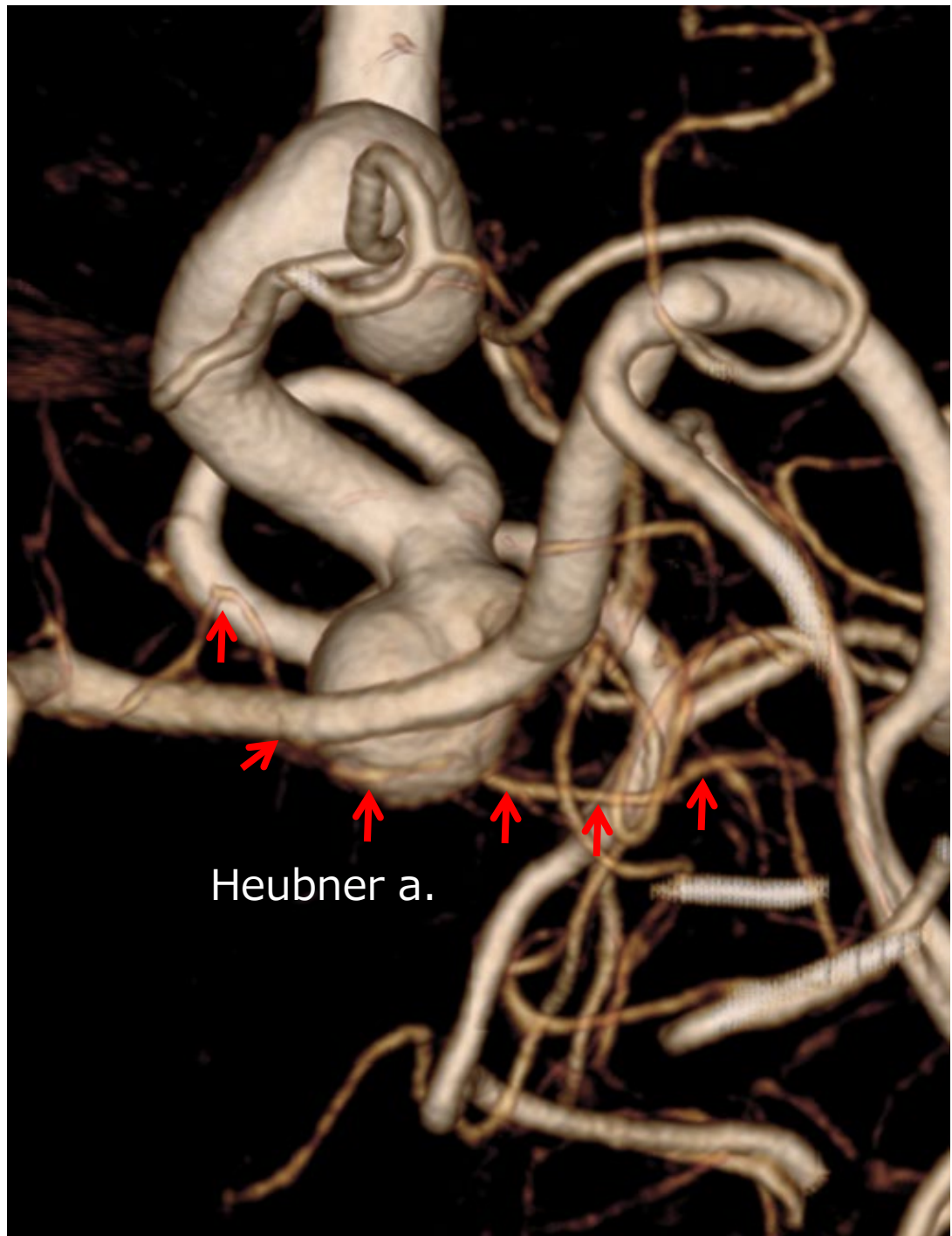
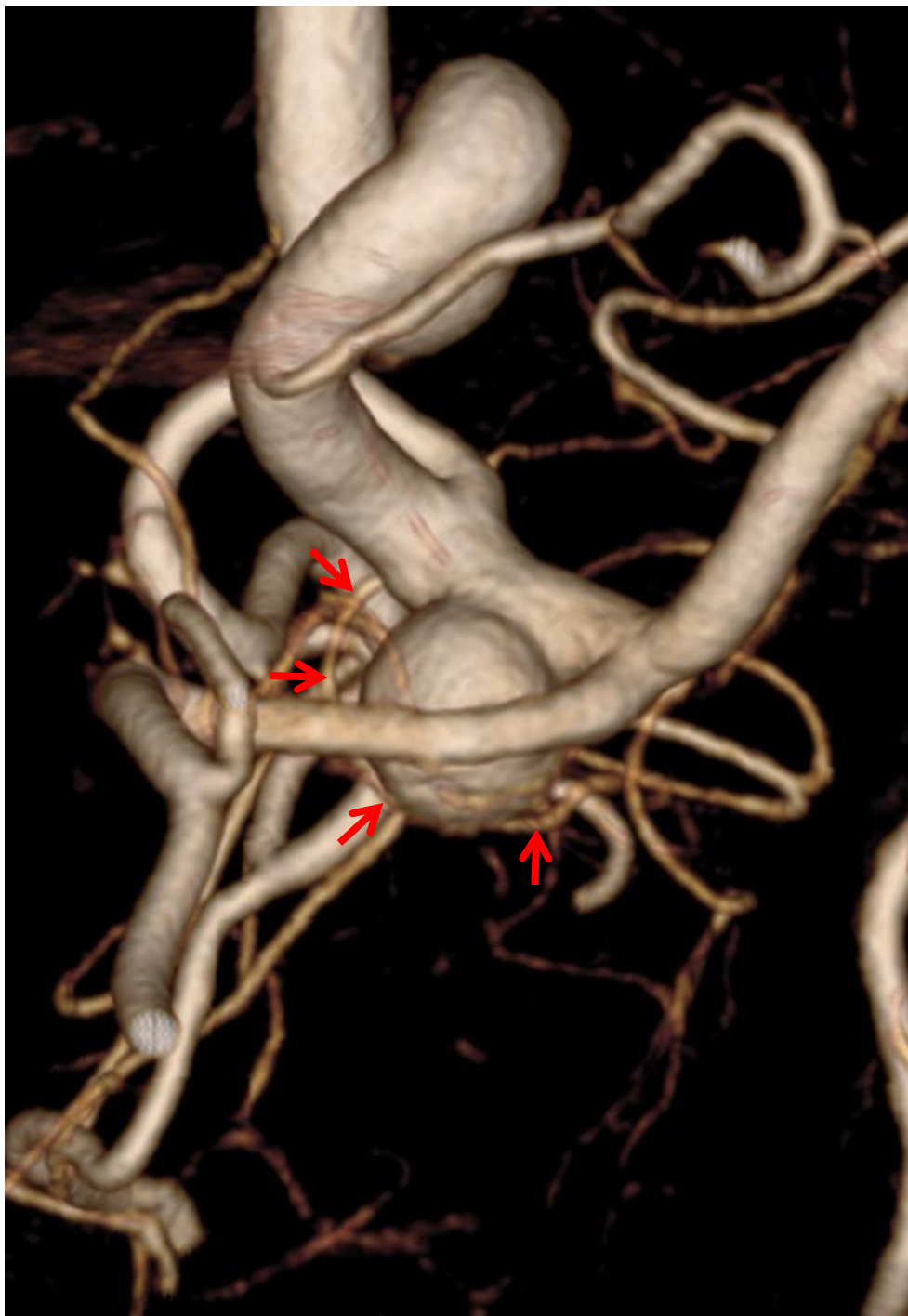AChoA

P

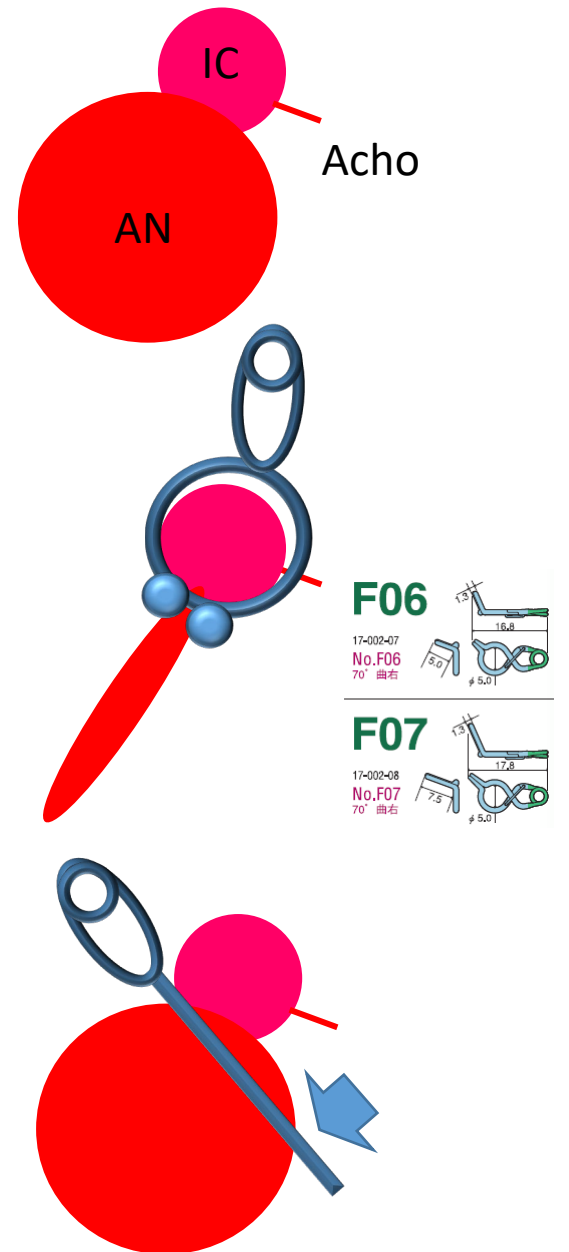
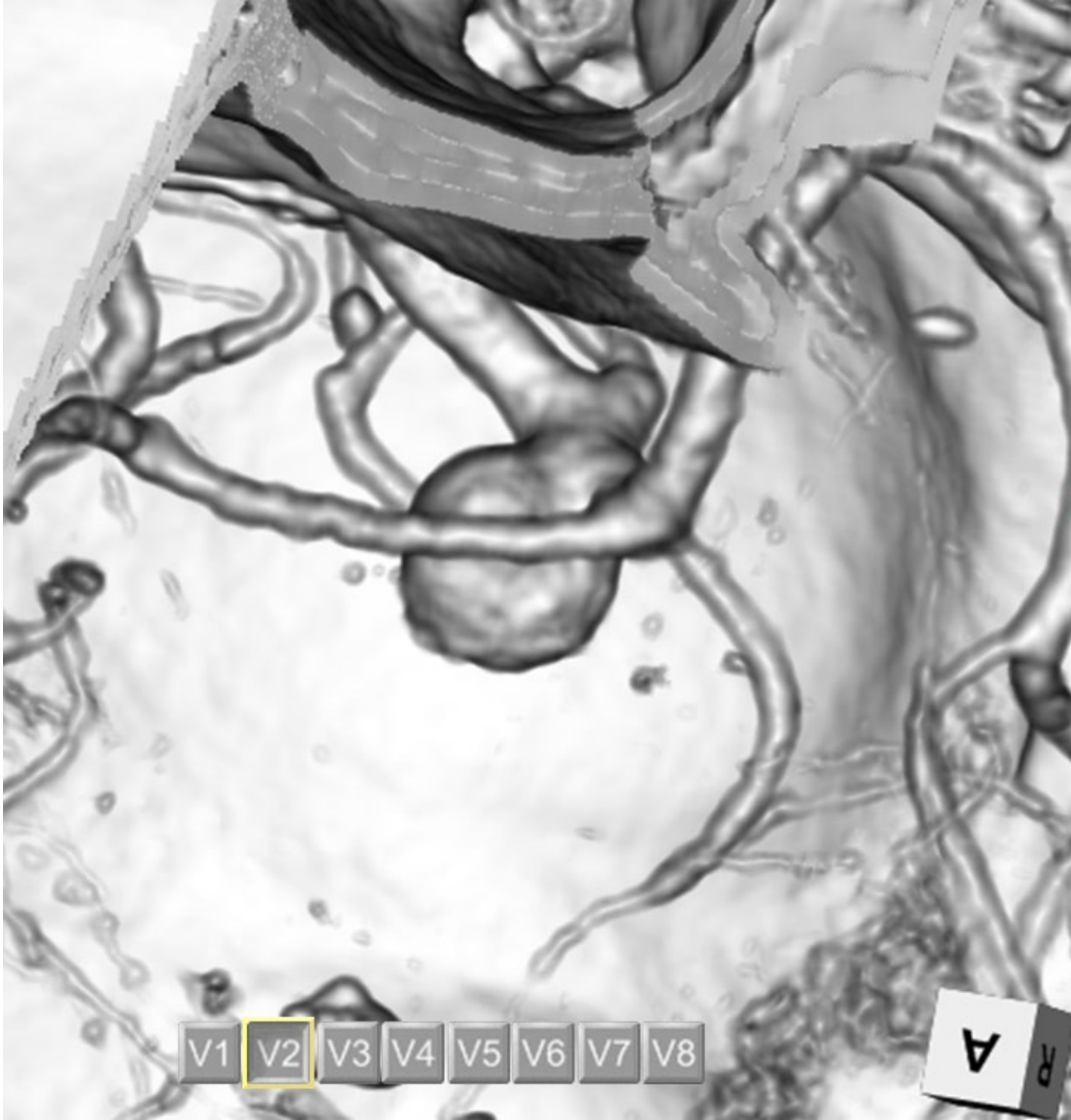


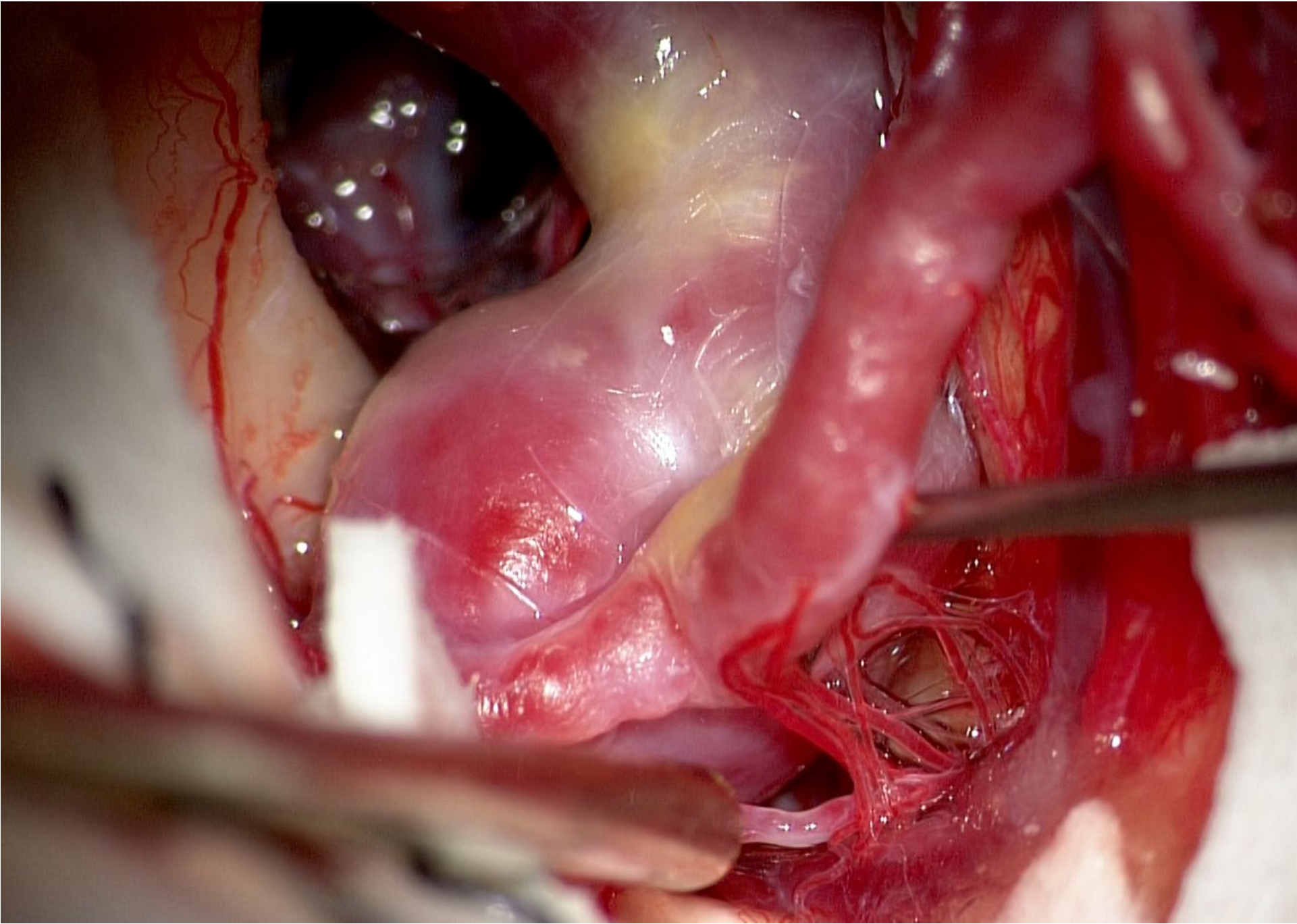
23 cm



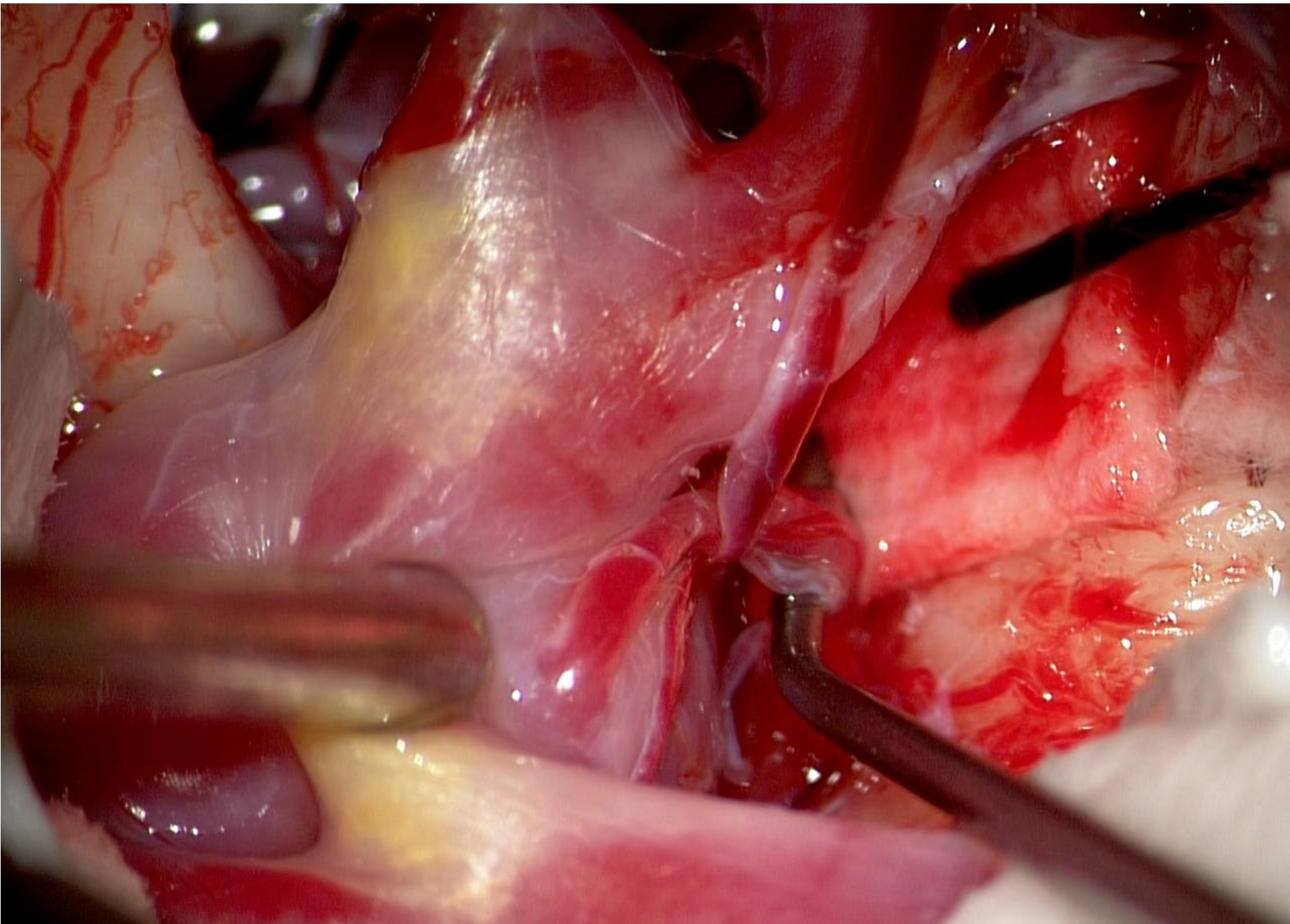




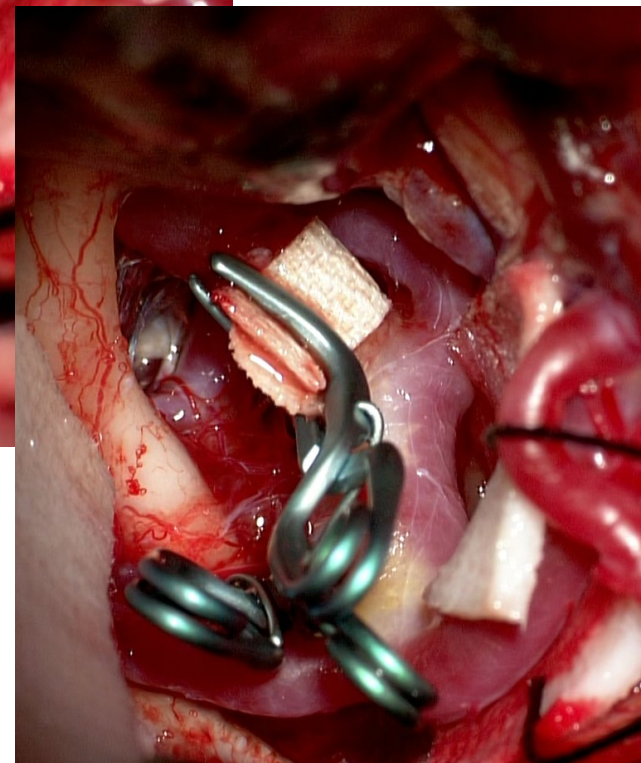
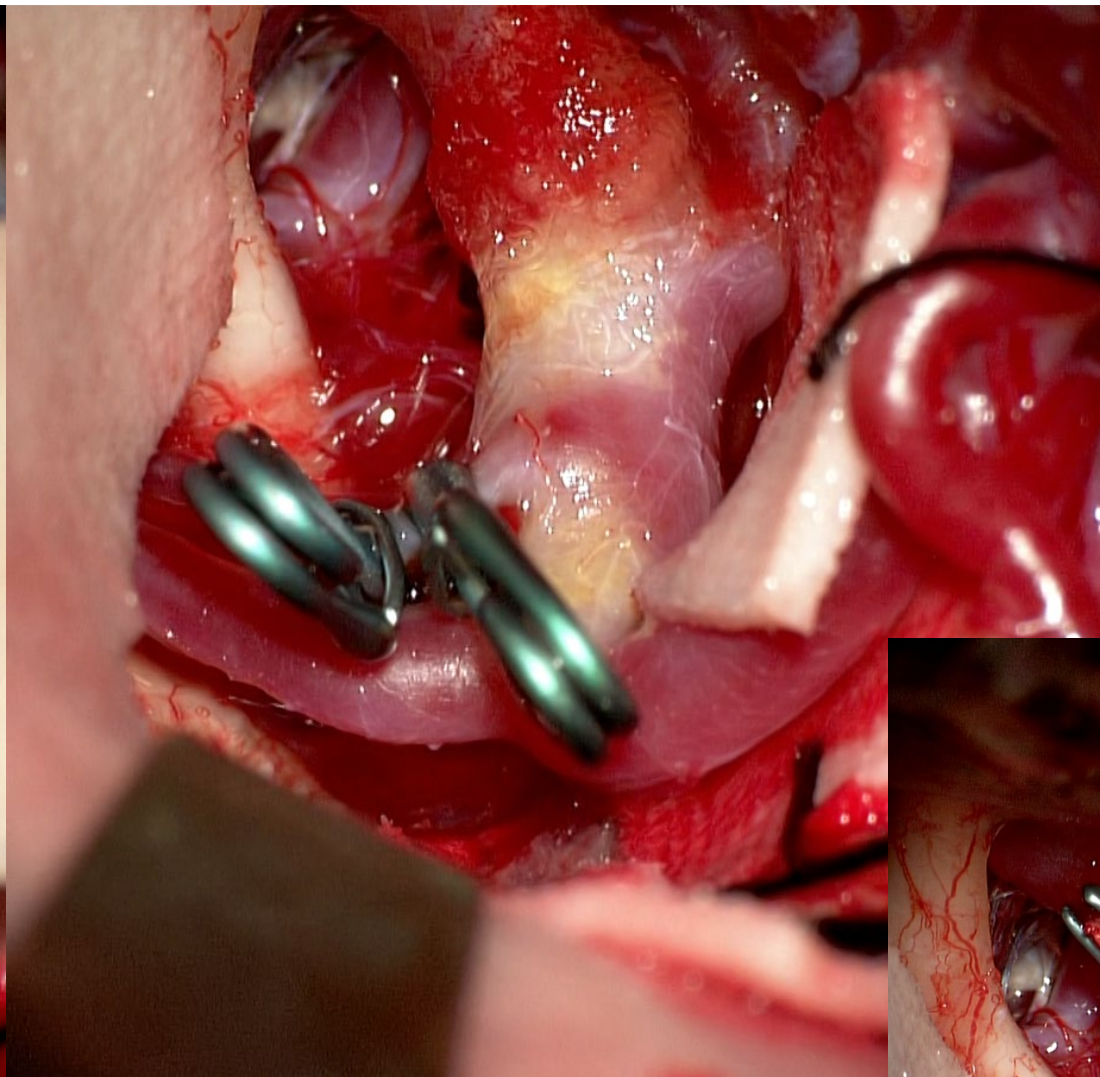
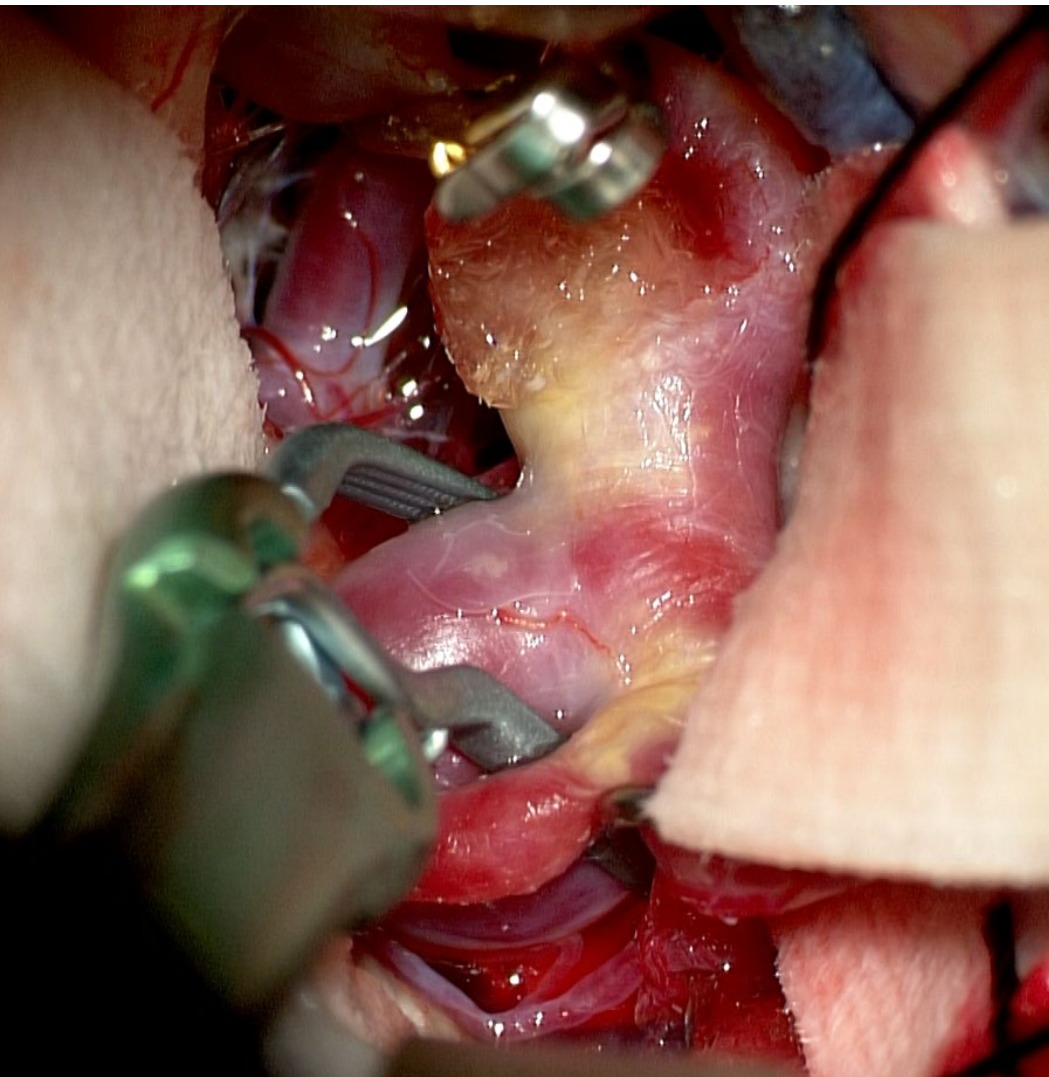




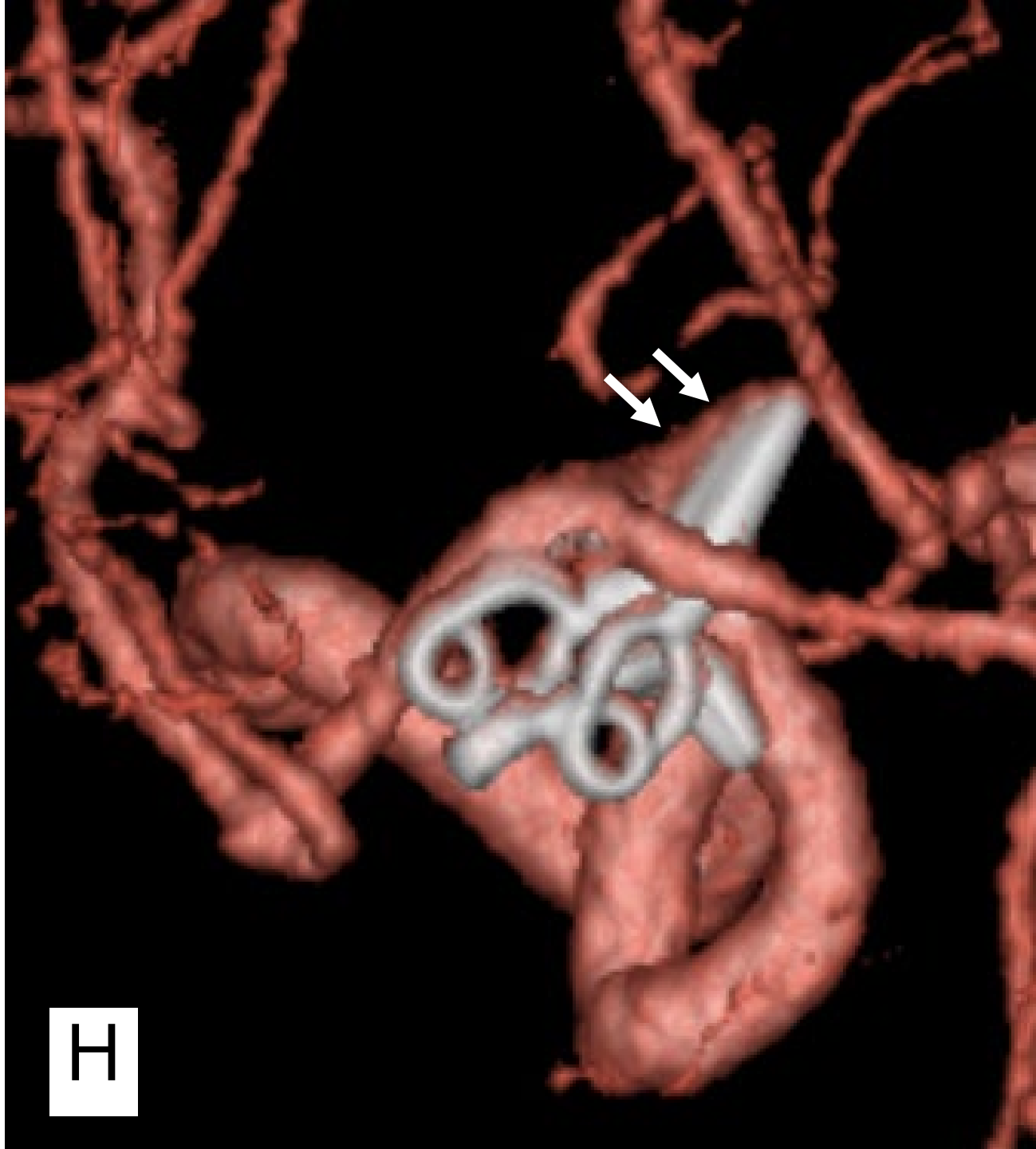



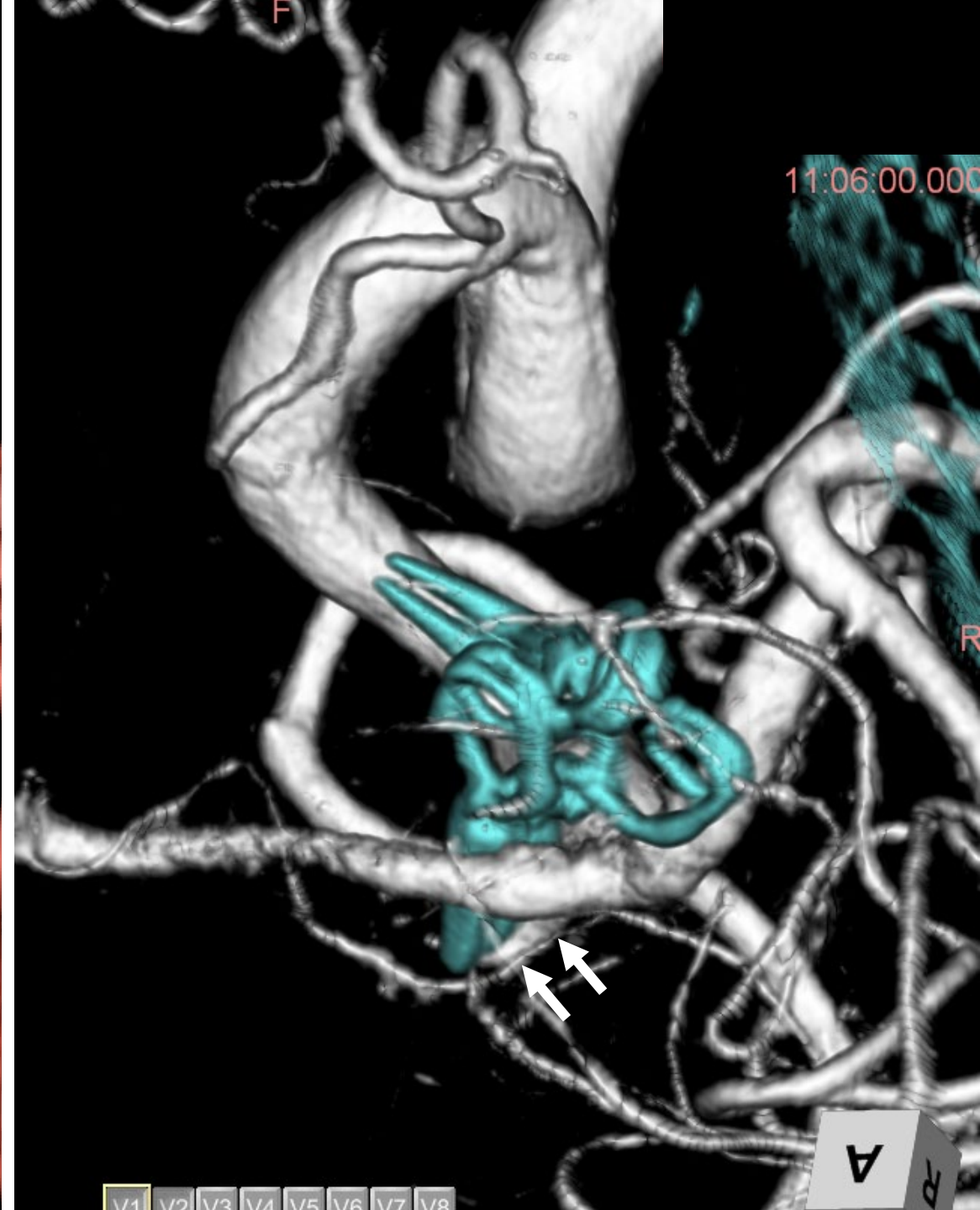




IC前壁から出血あり  
muscle piece + Hemasheld<sup>®</sup> + clip



H

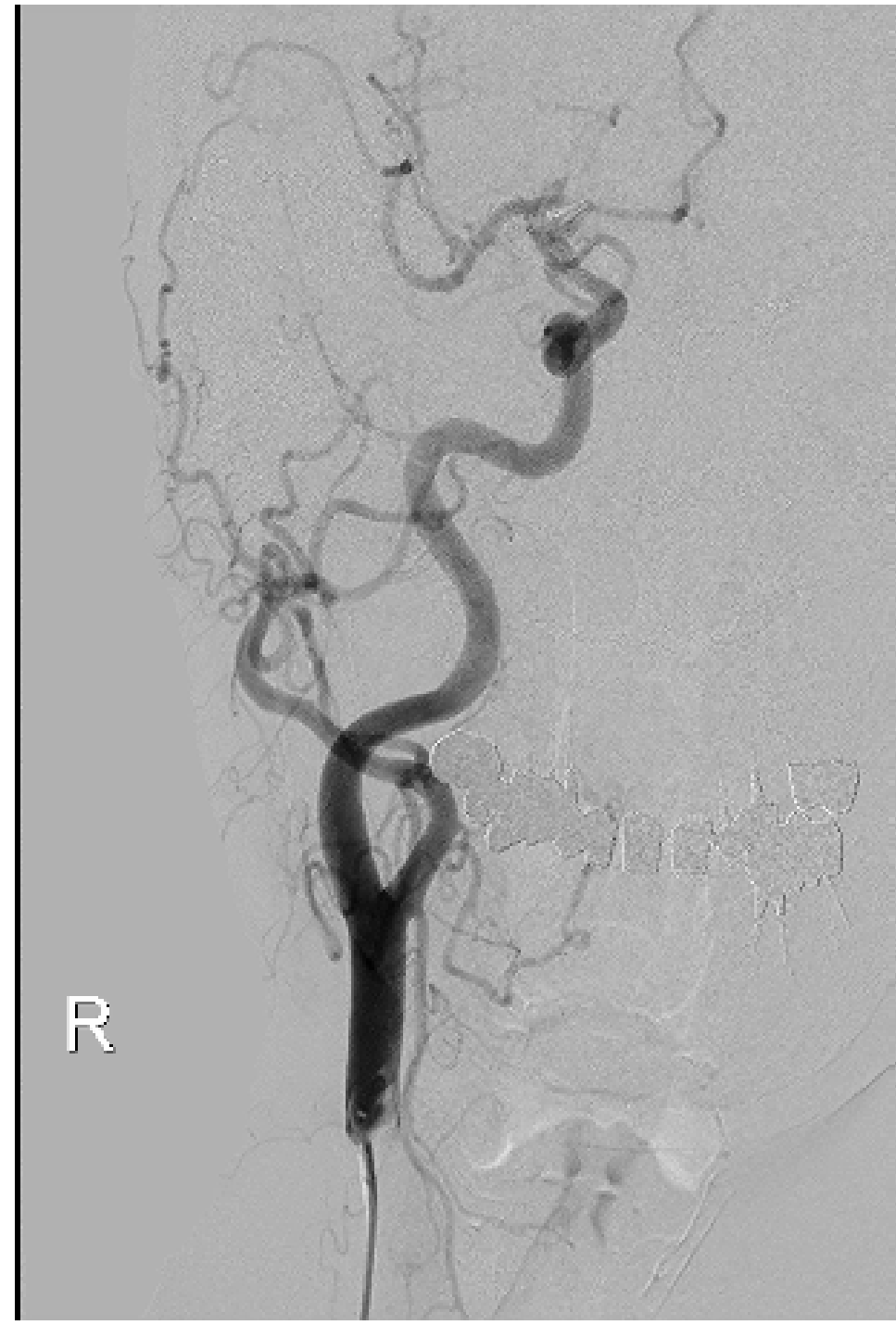
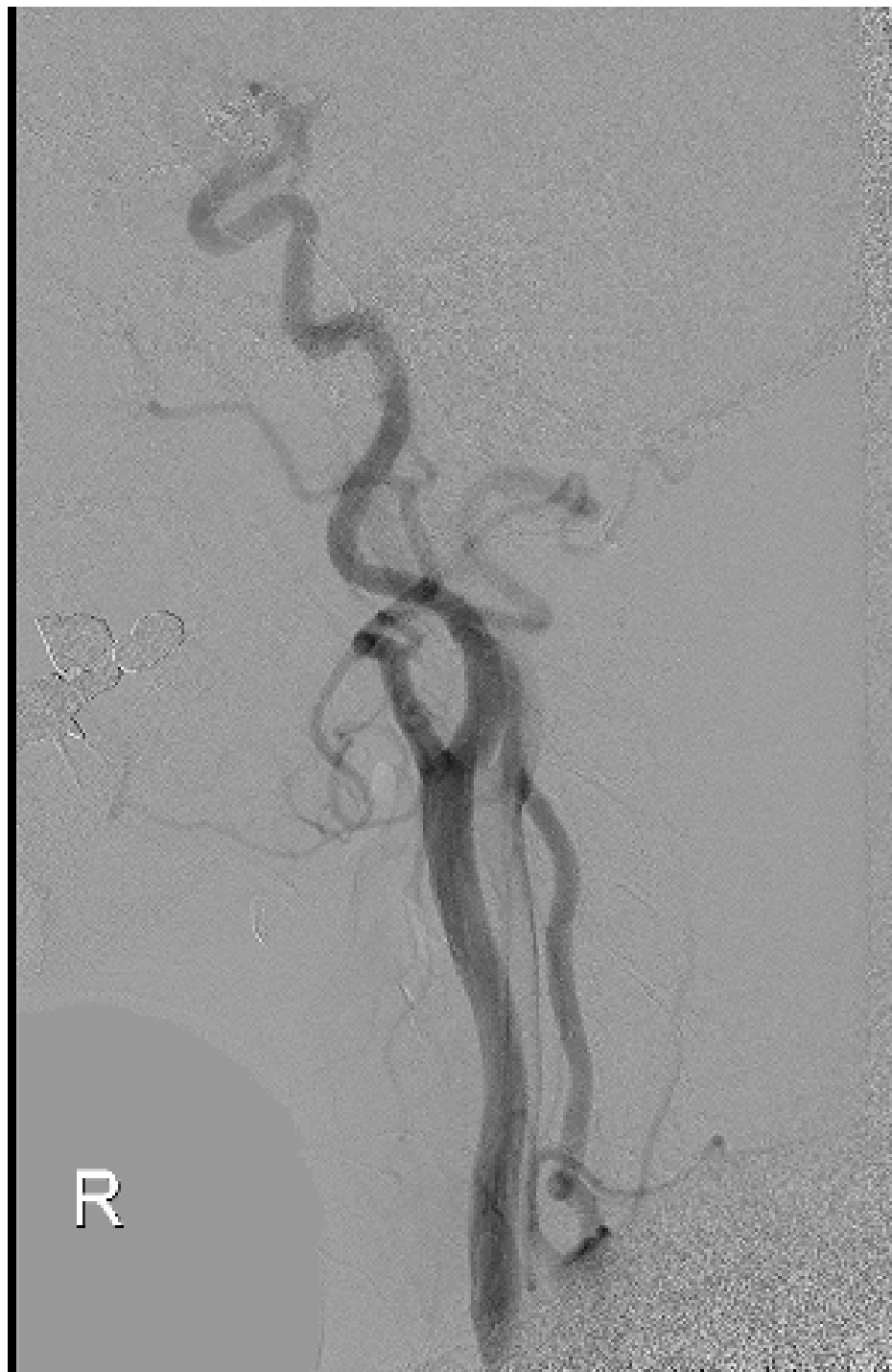

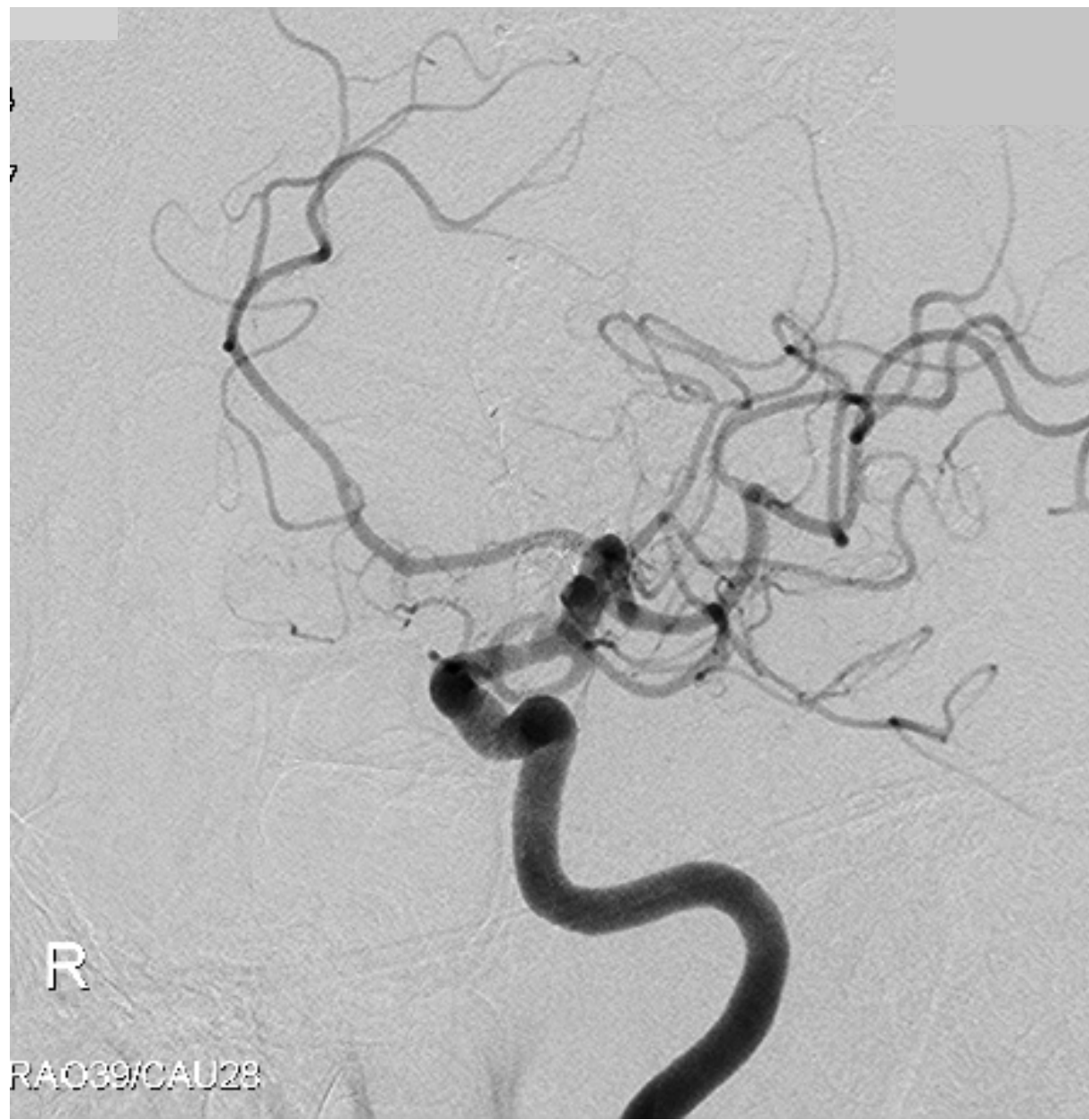
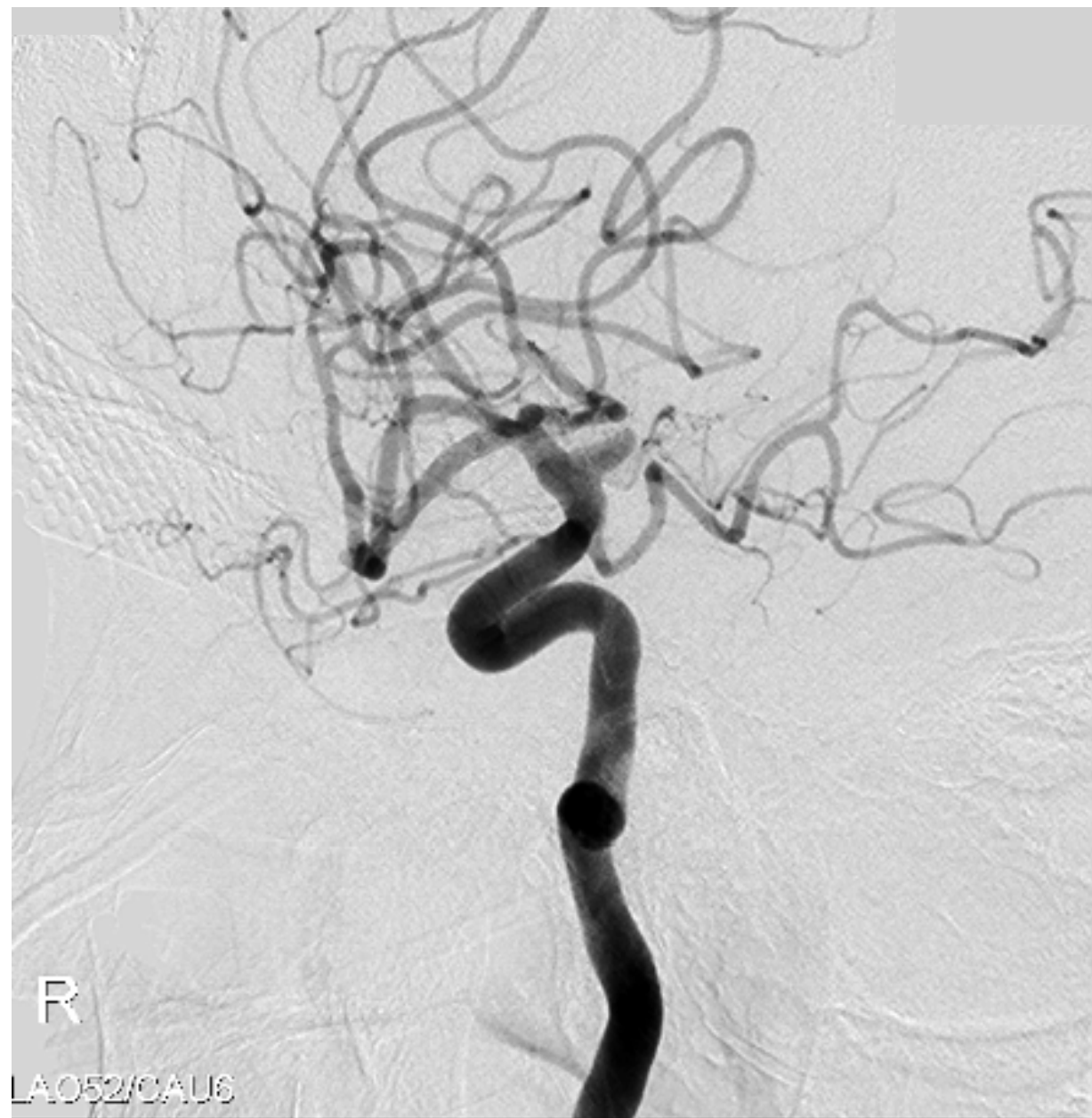V1 V2 V3 V4 V5 V6 V7 V8

11:06:00.000

A







## 症例7



# 39y.M 未破裂右M2(superior trunk) 紡錘状大型動脈瘤

**Clipping→再発→SAC→再発**

【既往歴】 特記事項なし

【X年紹介時内服薬】 バイアスピリン・タケキャブ

【現病歴】

X-7年12月頭部外傷を機に発見された右MCA大型瘤に対し血管形成的clipping

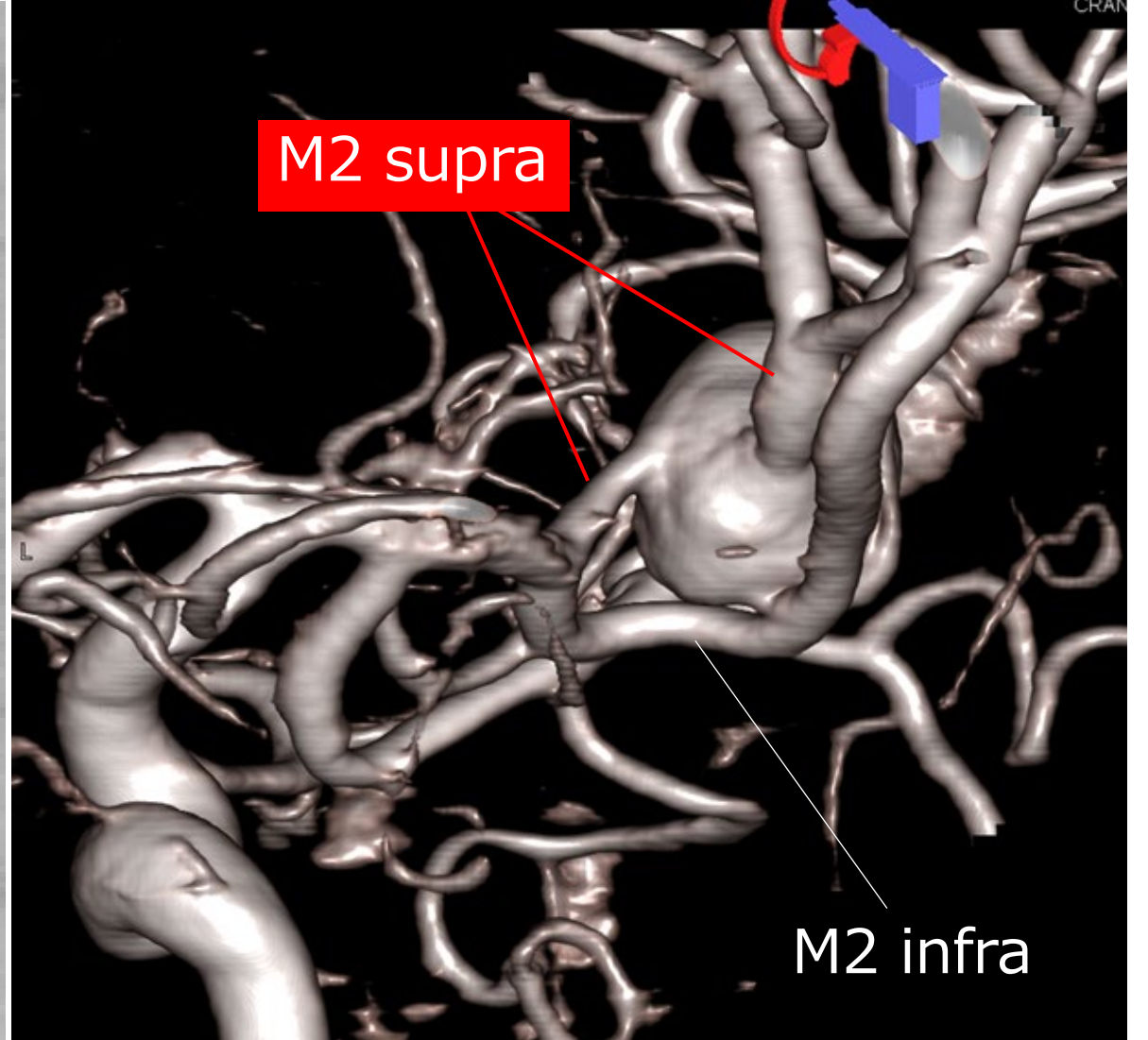
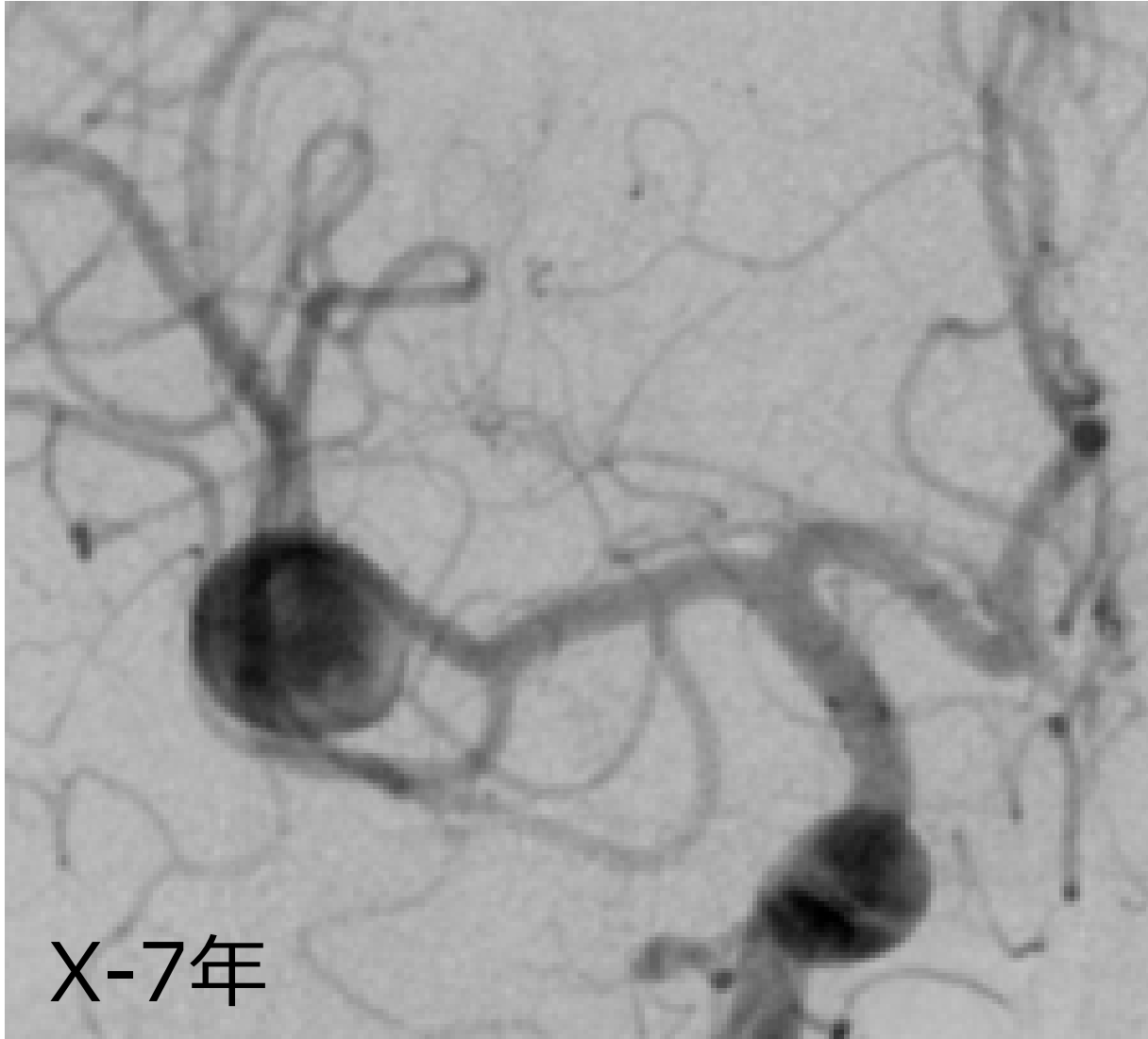
X-1年 2月 再発を確認（血流腔6mm）

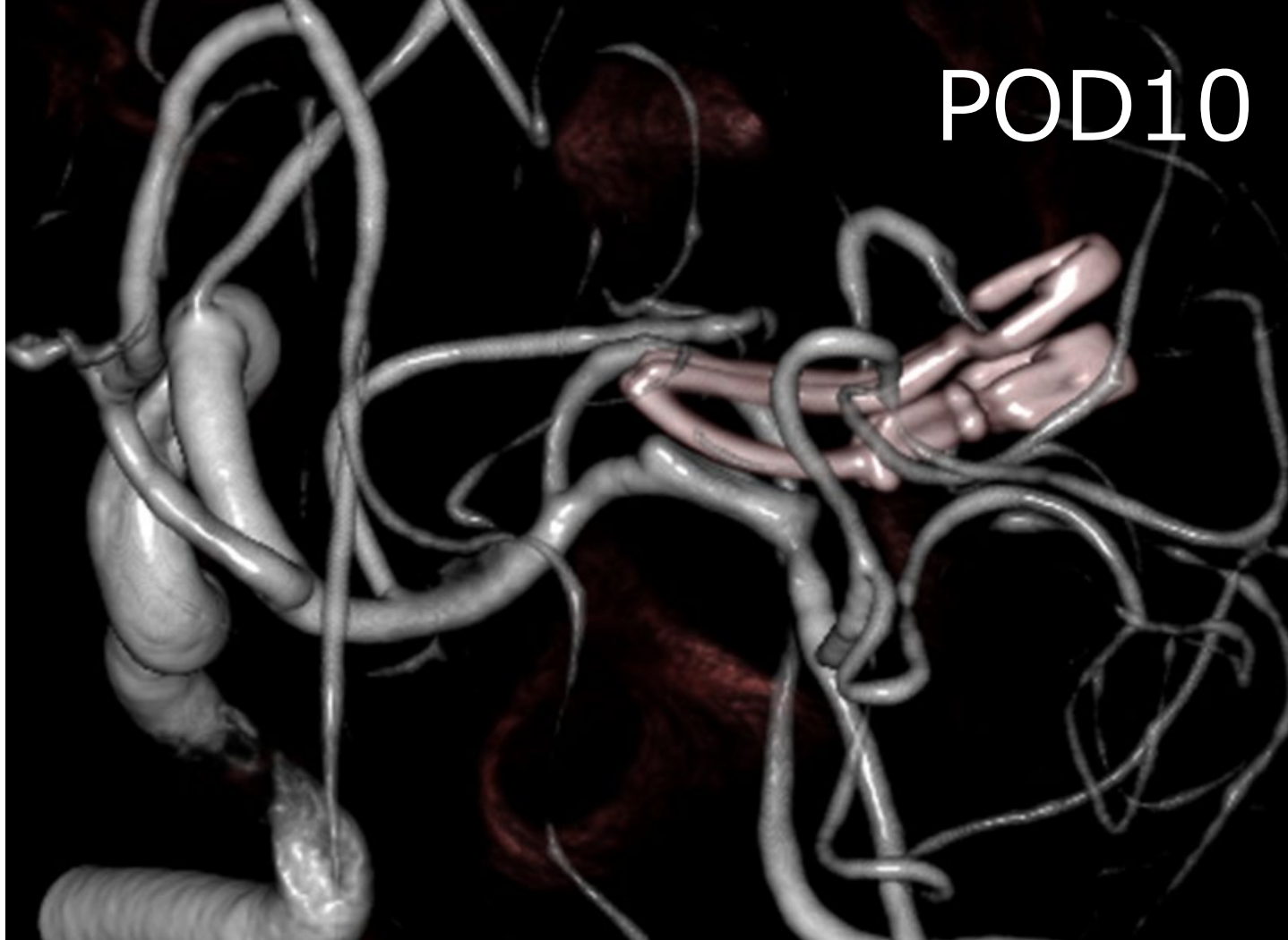5月 Stent-assisted coiling

12月 再々発を確認（血流腔9.7mm）

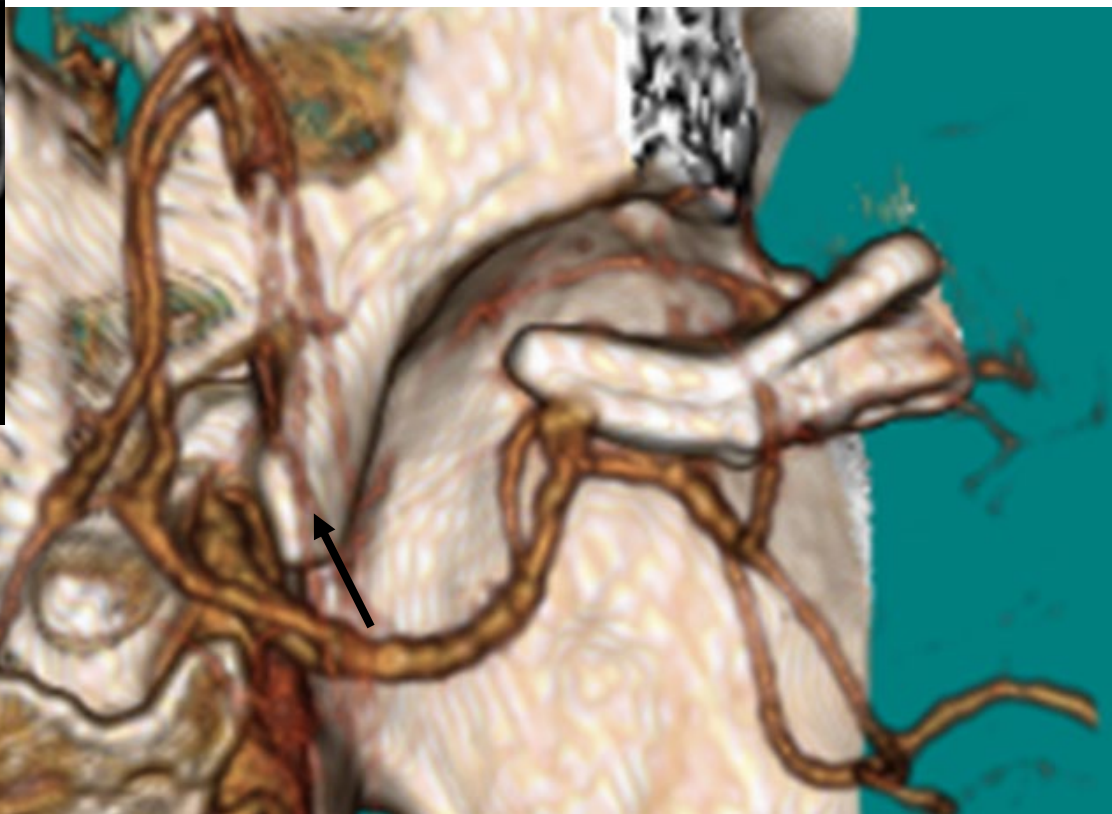
X年 2月 紹介初診

【神経学的所見】 異常なし





POD10



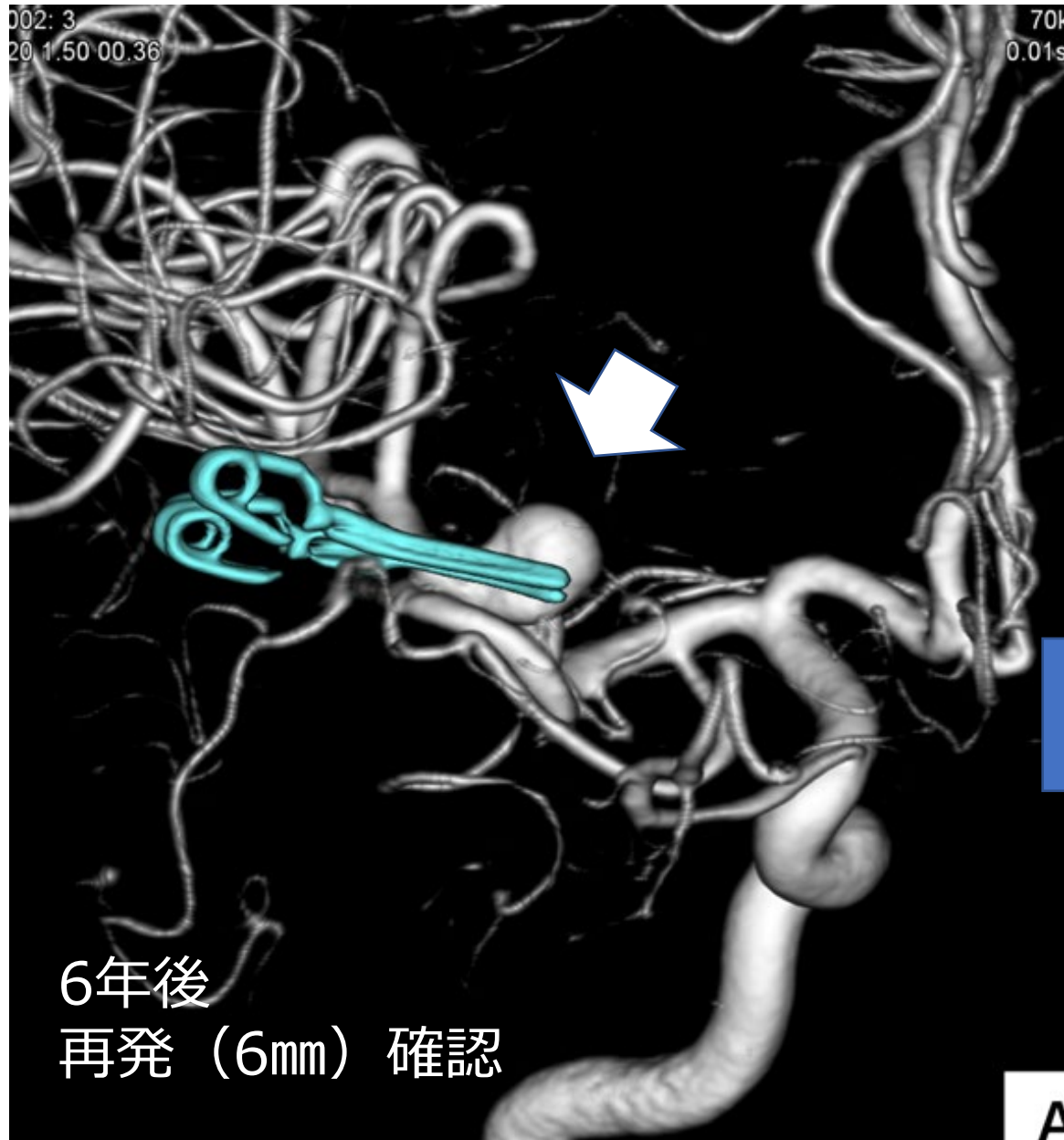
POM9

再発なし

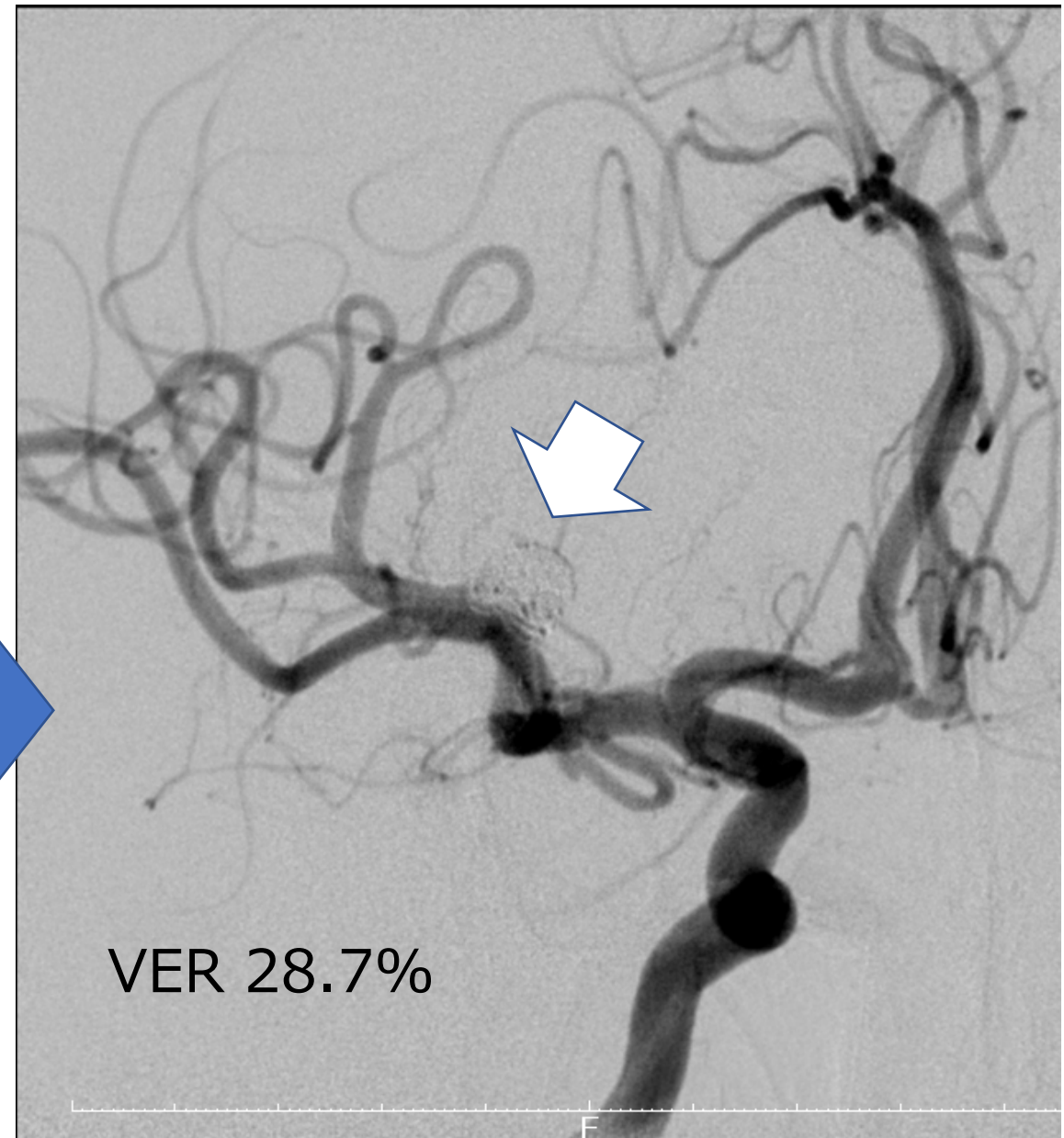
X-7年12月  
血管形成的clipping術



X-1年2月 DSA

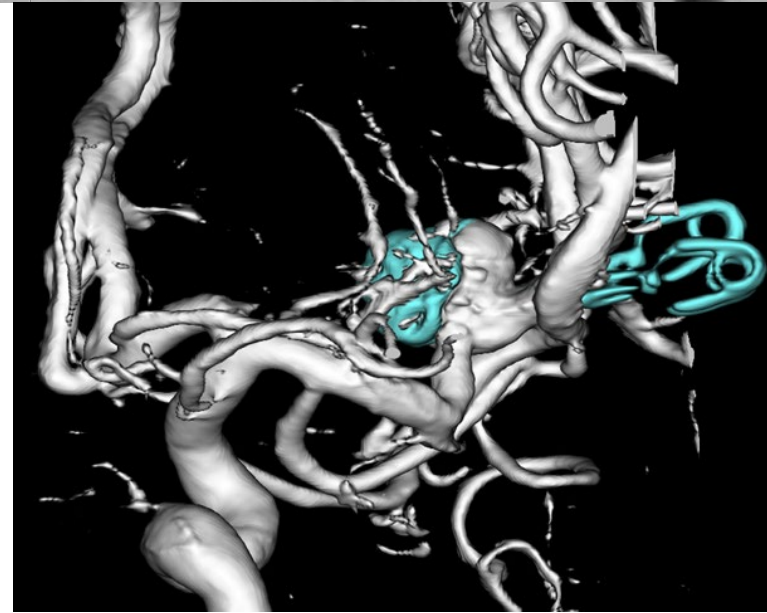
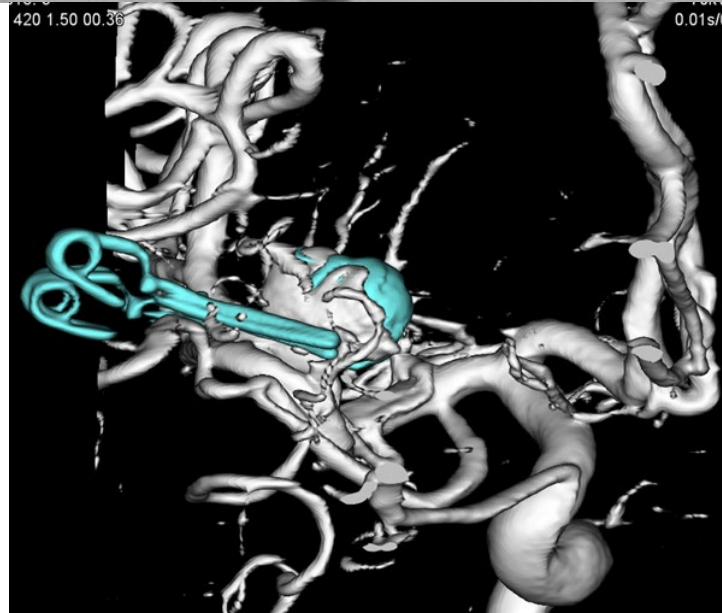
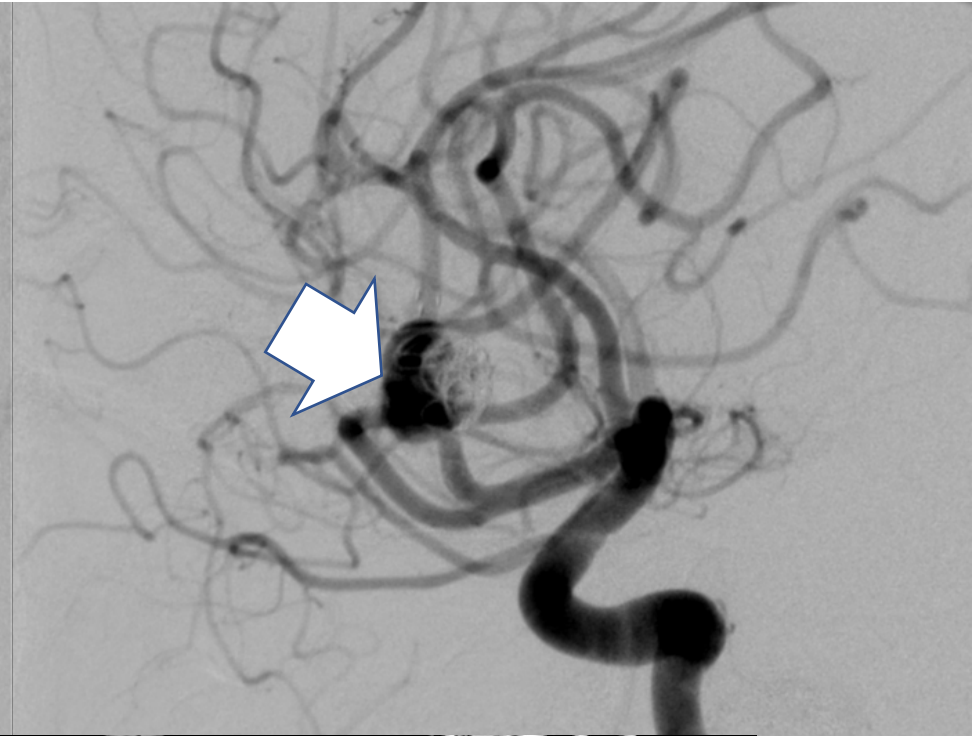
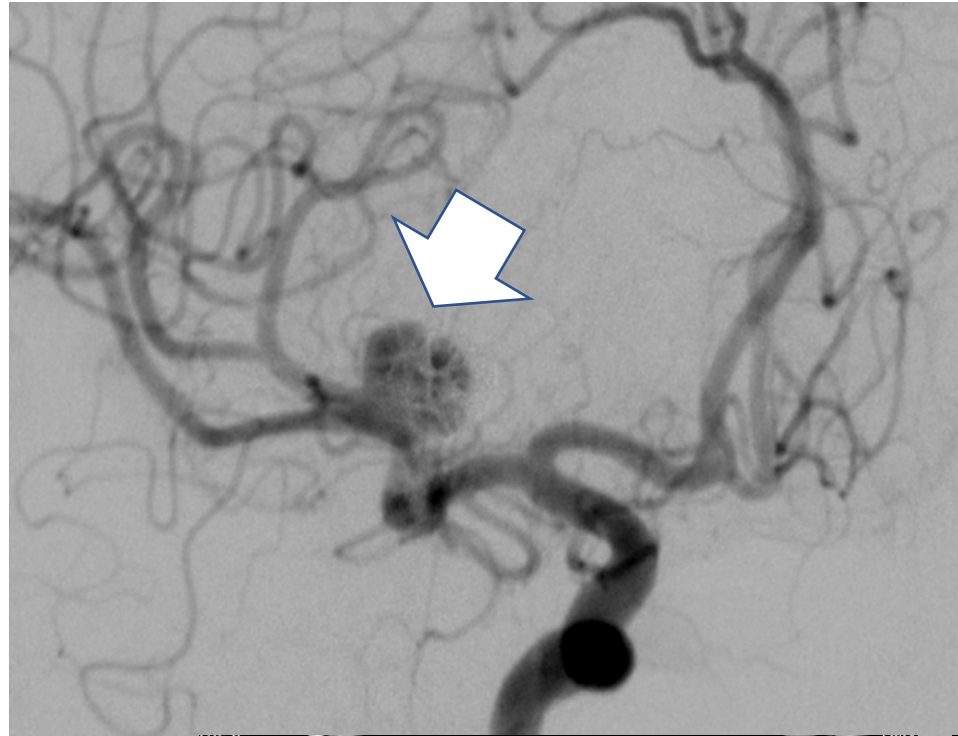


X-1年5月 Stent-assisted coiling



X-1年12月 (6ヵ月後)

再々発確認 (9.7mm)

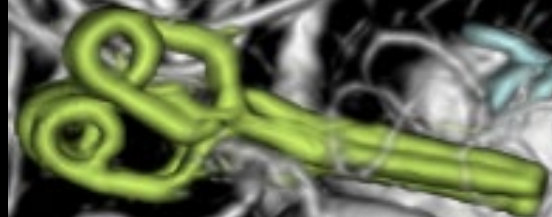



X年3月

M2 supra

M2 infra



Thickness: 0.25mm

XA VR

LAO: 0.0

CRA: 0.0

A

.25mm

Mask Volum 1.04x71.

Mask Volume (

X年3月



Stent distal marker

Stent Proximal marker

M2 supra

M2 infra

M1

MCA bifurcation

V1 V2 V3 V4 V5 V6 V7 V8

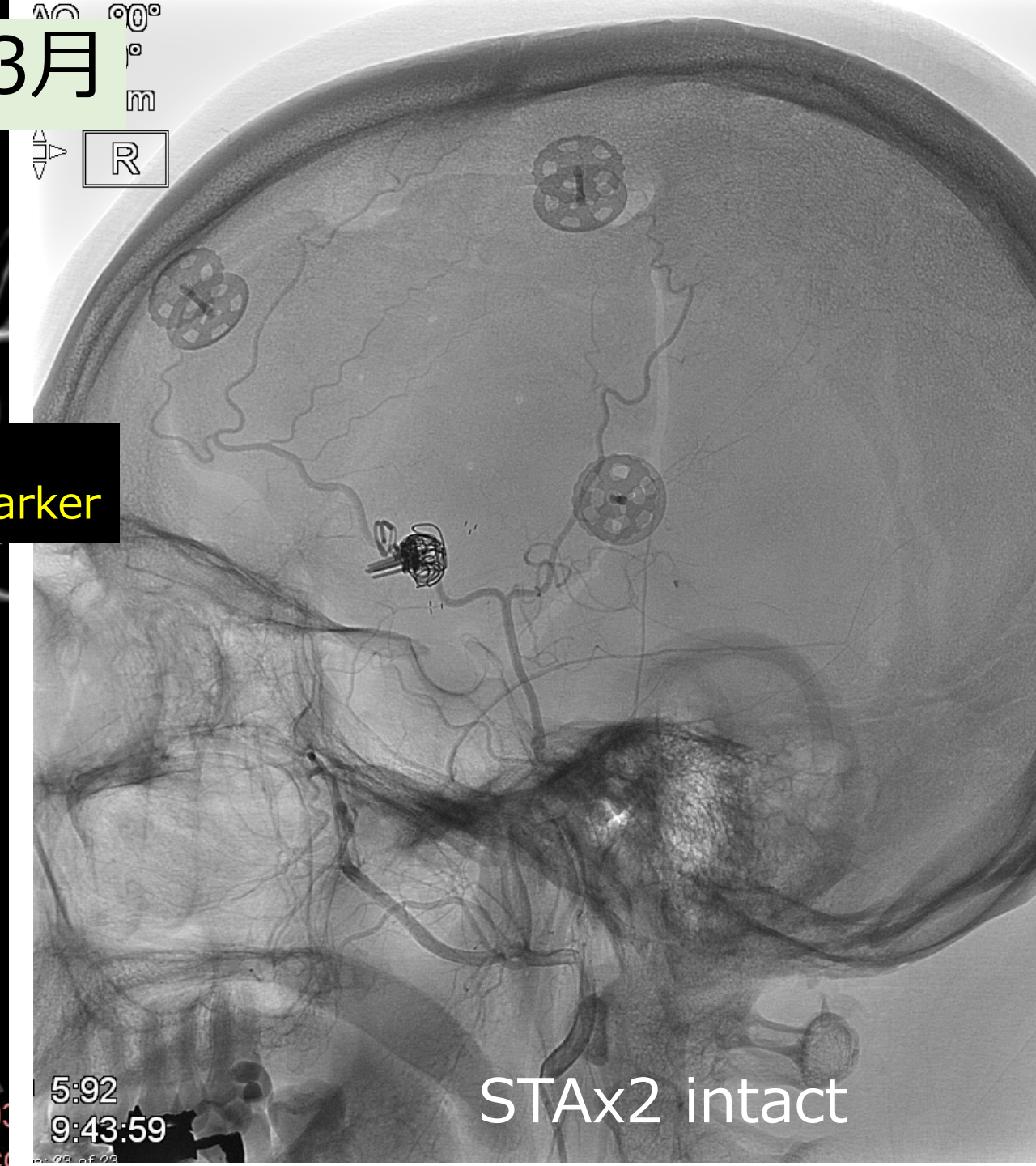
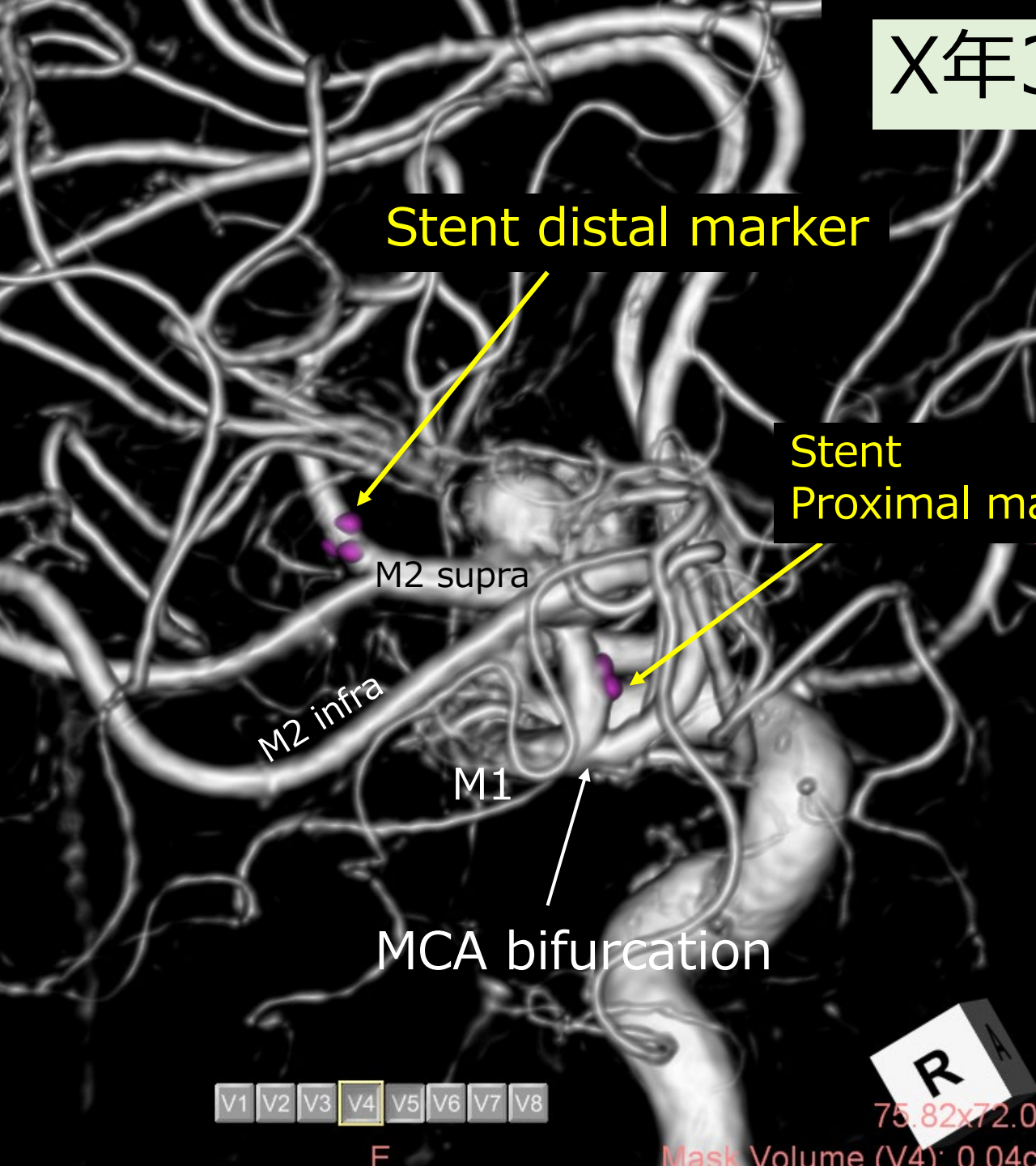
R

75.82x72.03

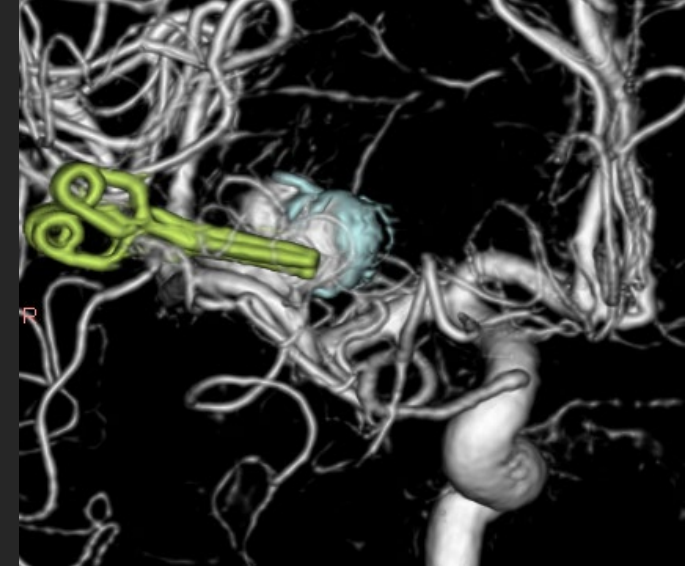
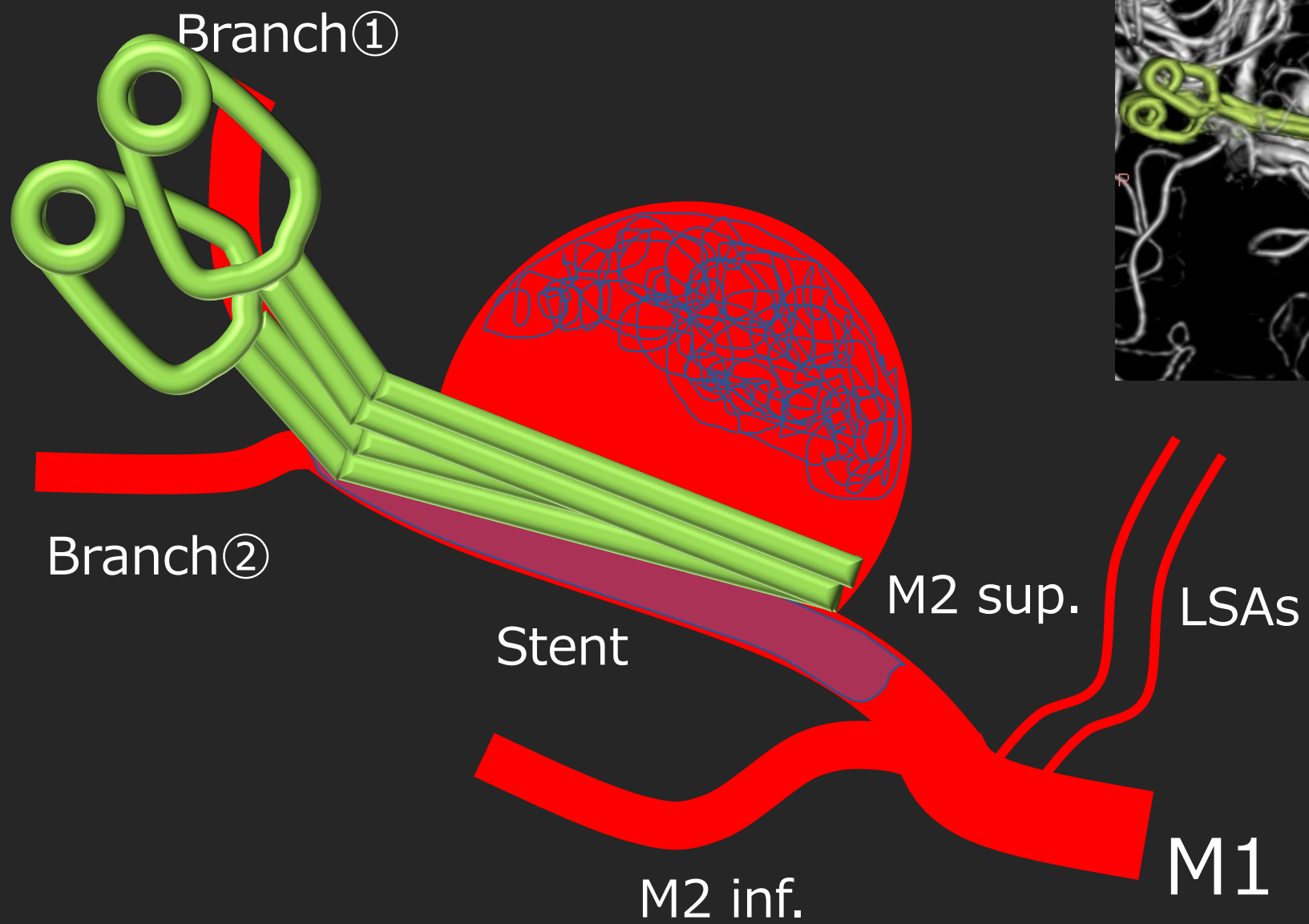
Mask Volume (V4): 0.04cc

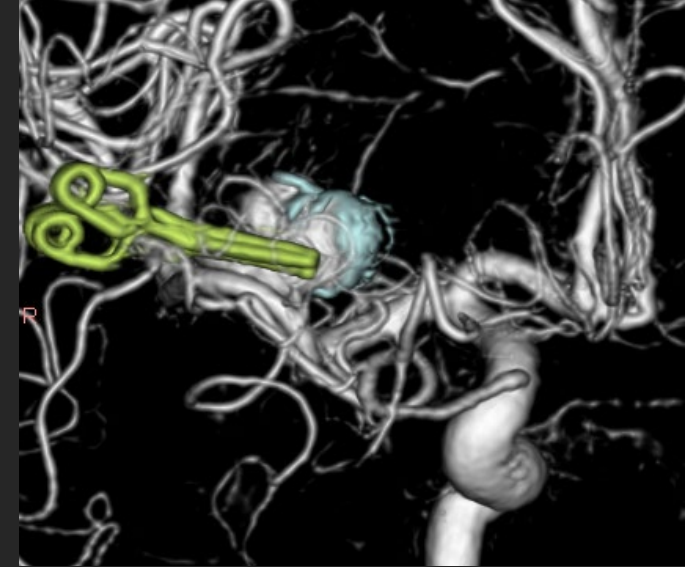
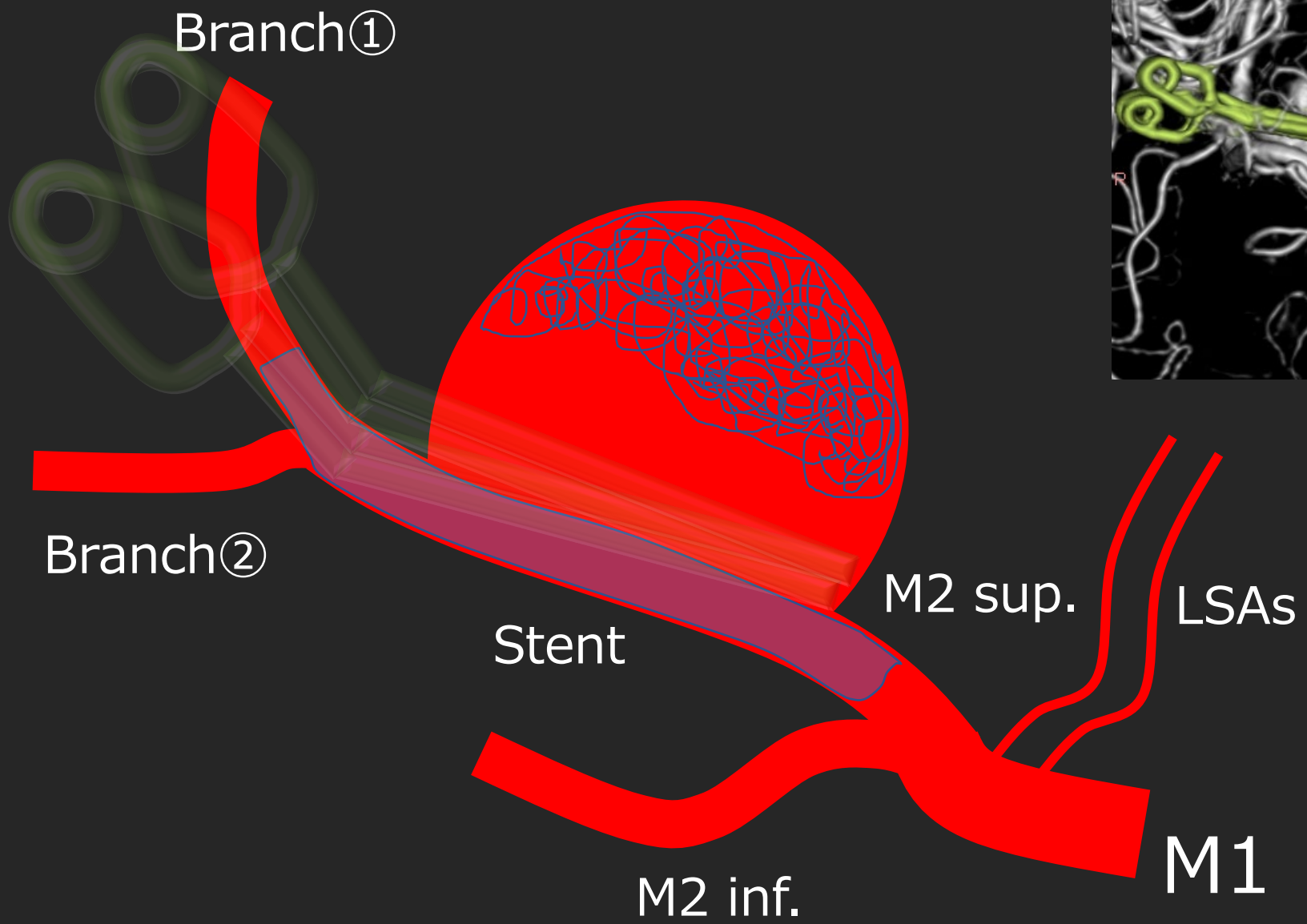
5:92  
9:43:59

STAx2 intact









# 検討事項

- 治療戦略
- 治療手技