

# The 3rd UTOPIA for CVD IVR Session Round Table Discussion

## Case 01

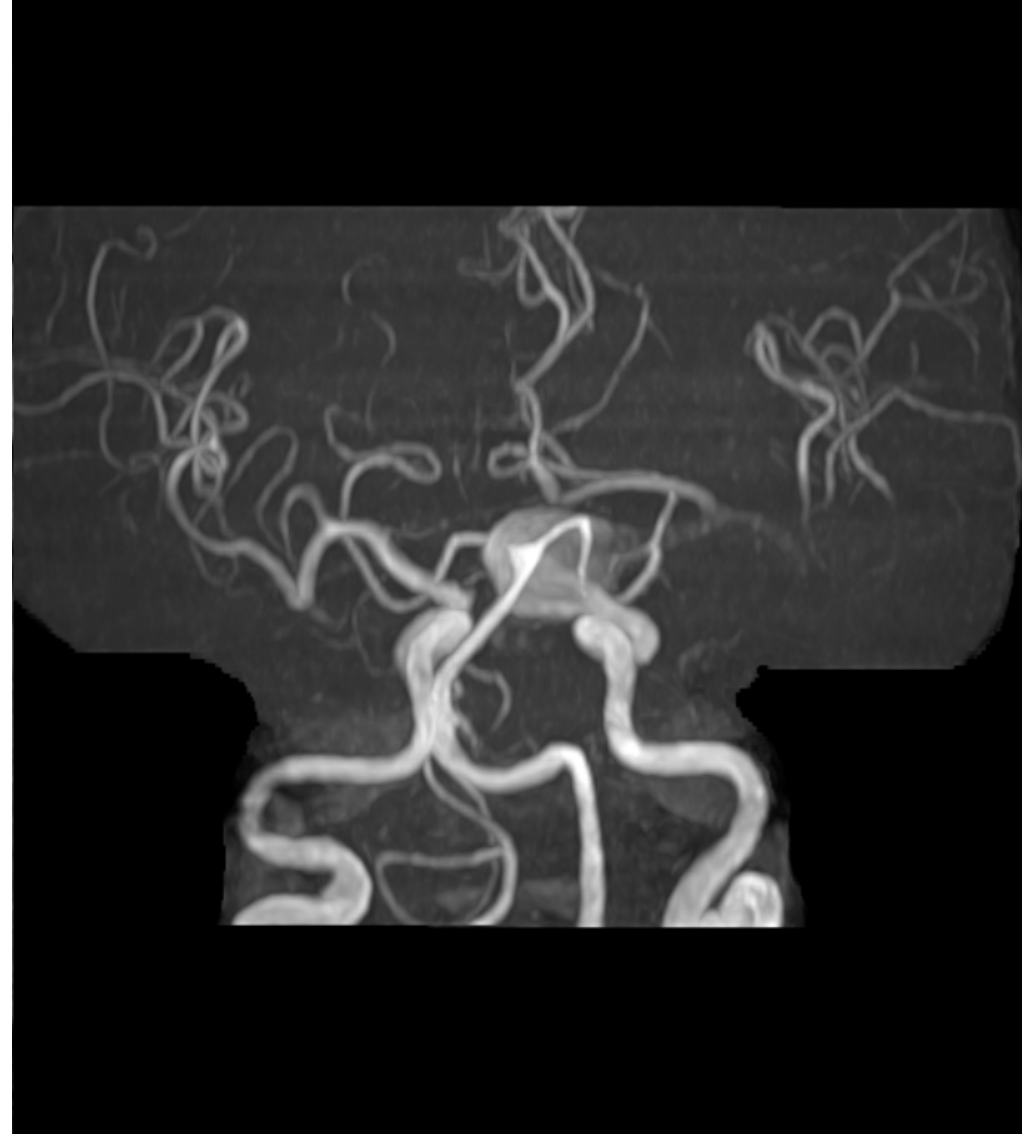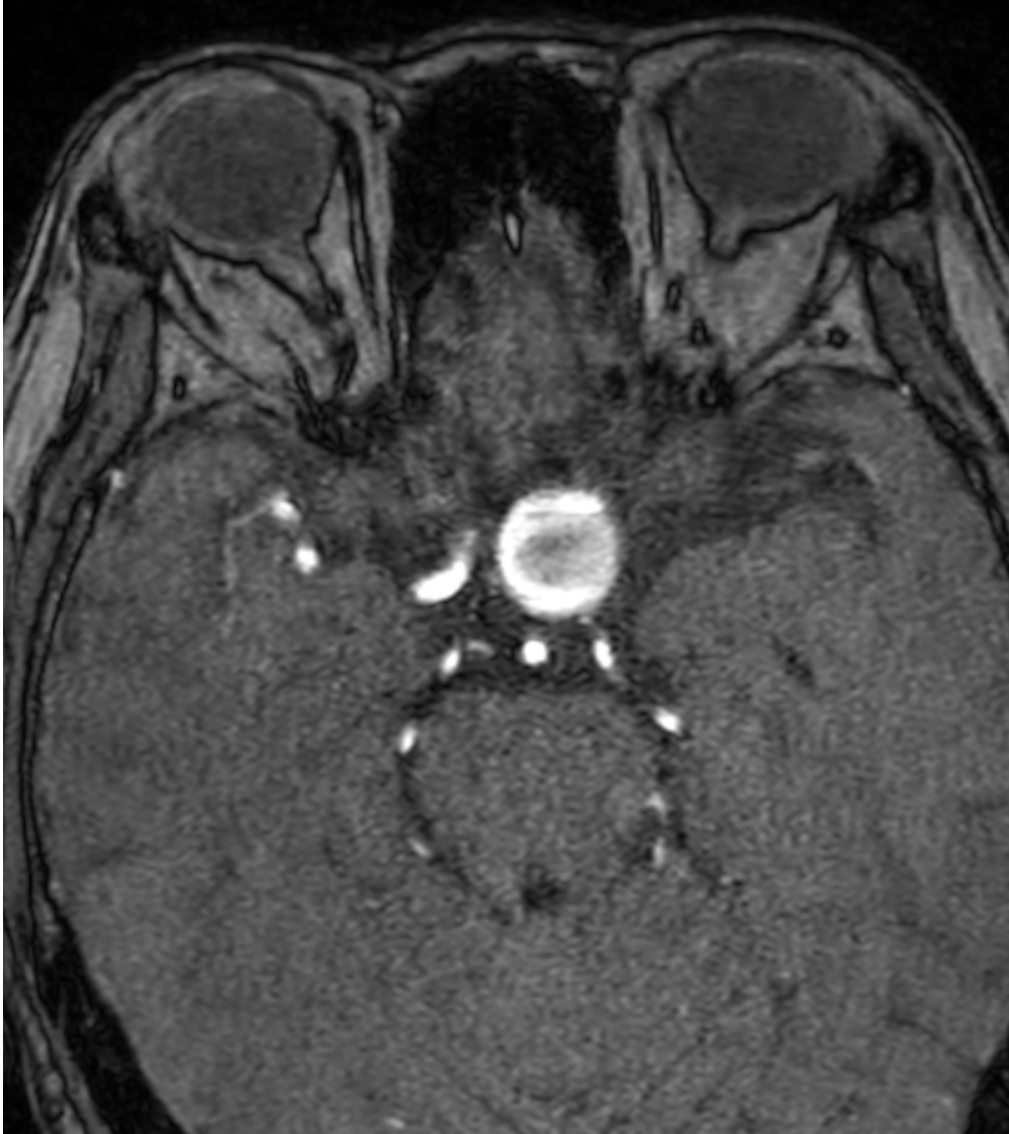
**58F**

**Lt. Paraclinoid AN  
(unruptured)**

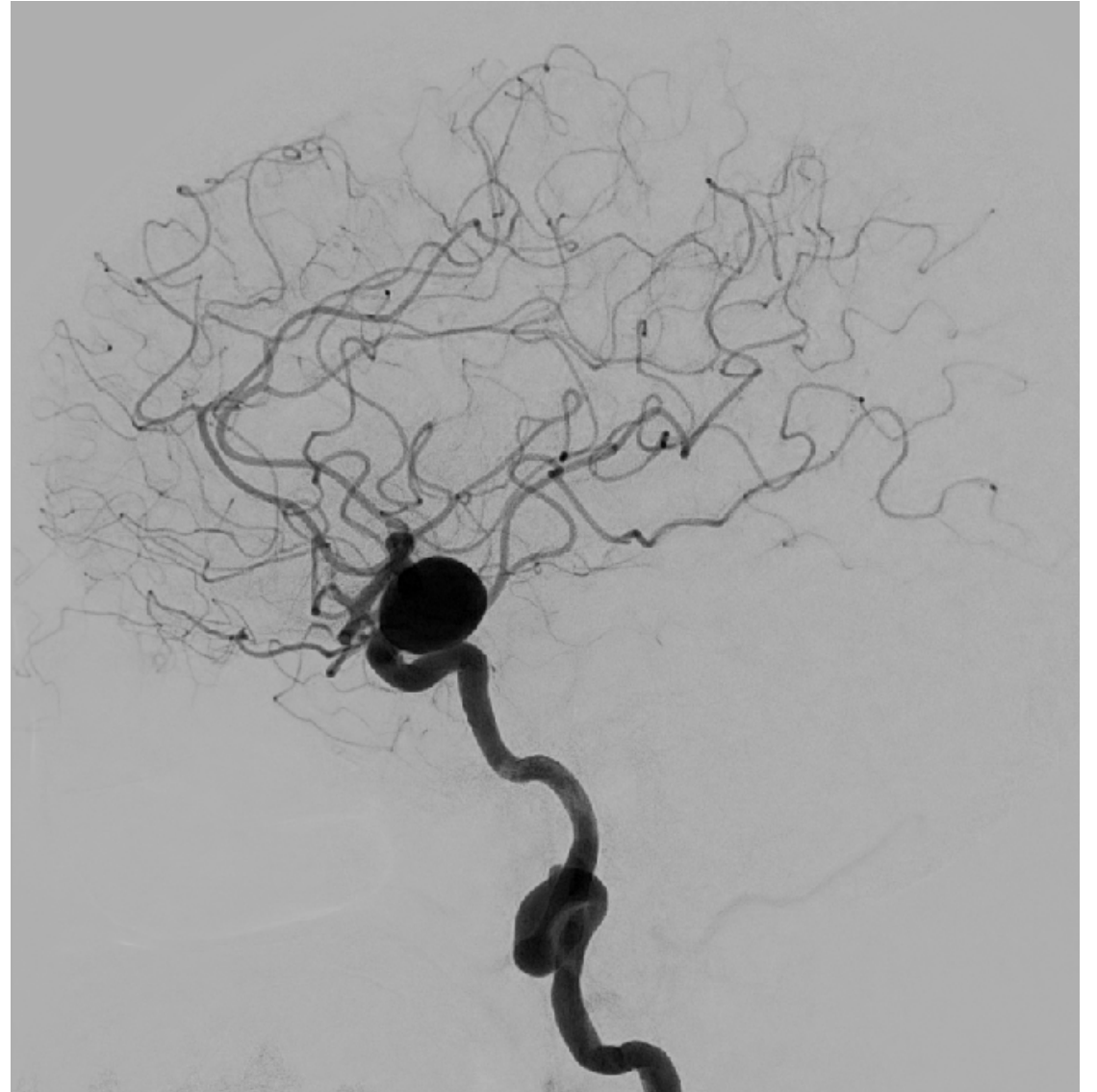
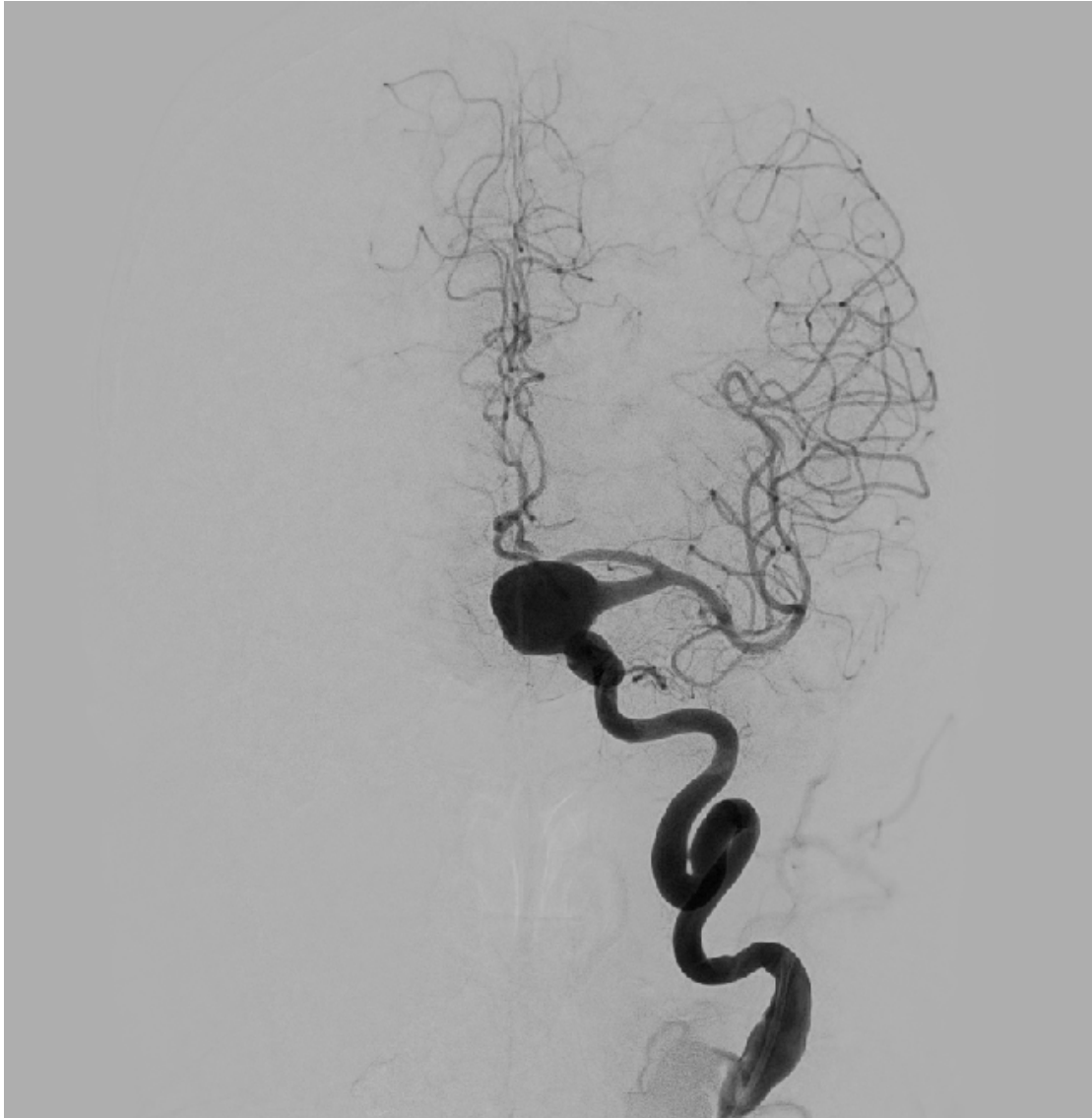## Case 01      58F

現病歴	めまいの精査で施行された頭部CTで未破裂脳動脈瘤を指摘され、当科紹介受診となった。
既往歴	片頭痛 その他特記すべき事項なし
内服薬	ミグシス、クリアミン
生活歴	特記すべき事項なし
現症	視力視野正常 その他神経脱落症状なし

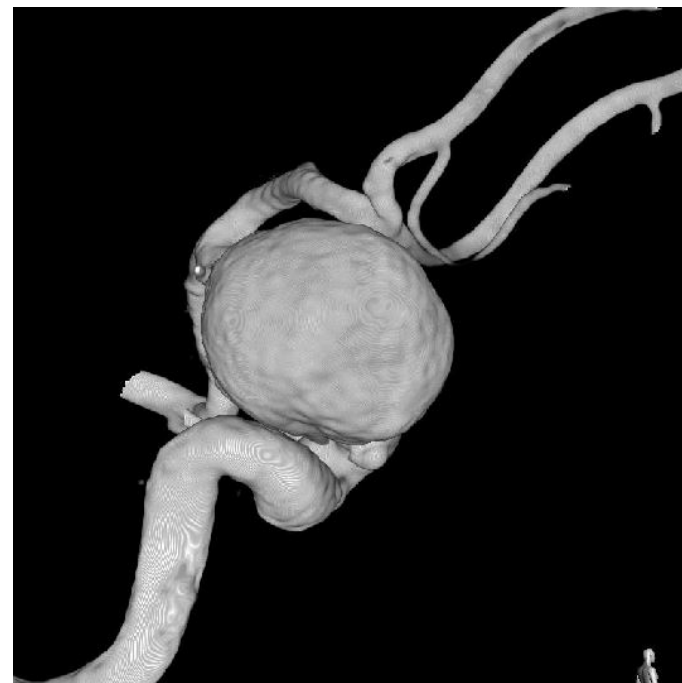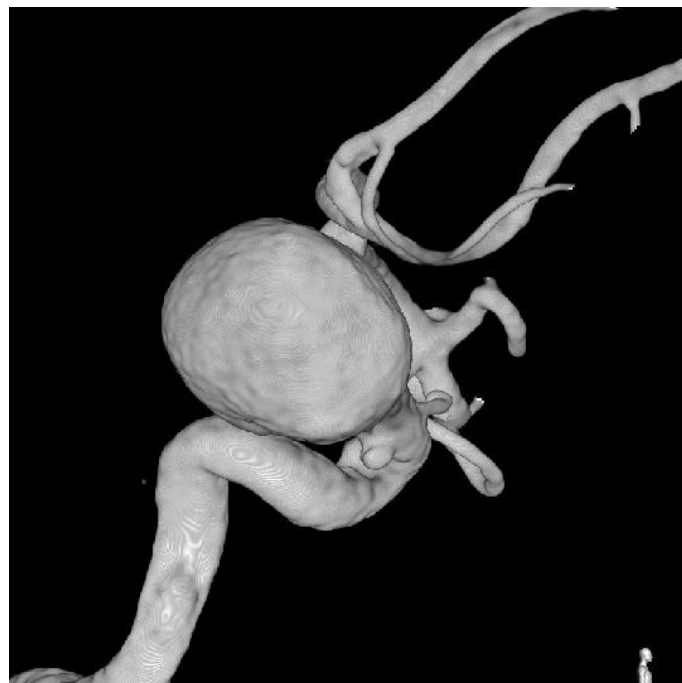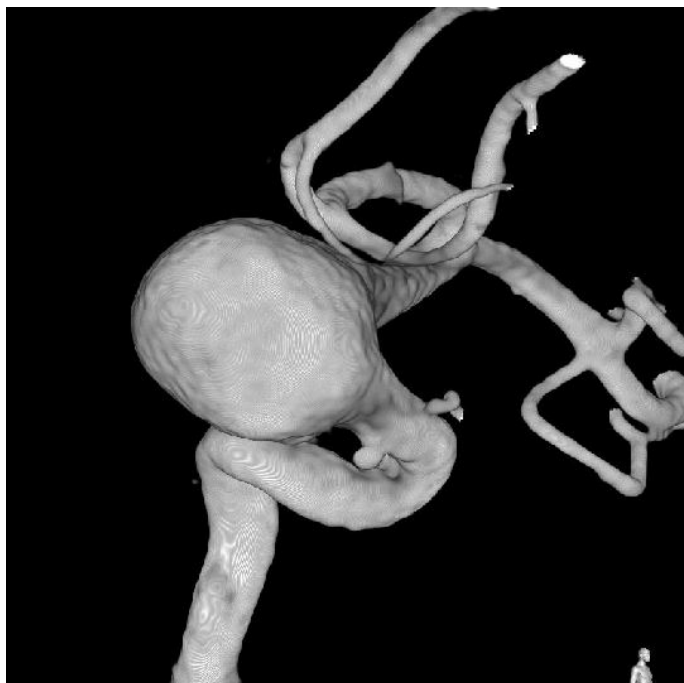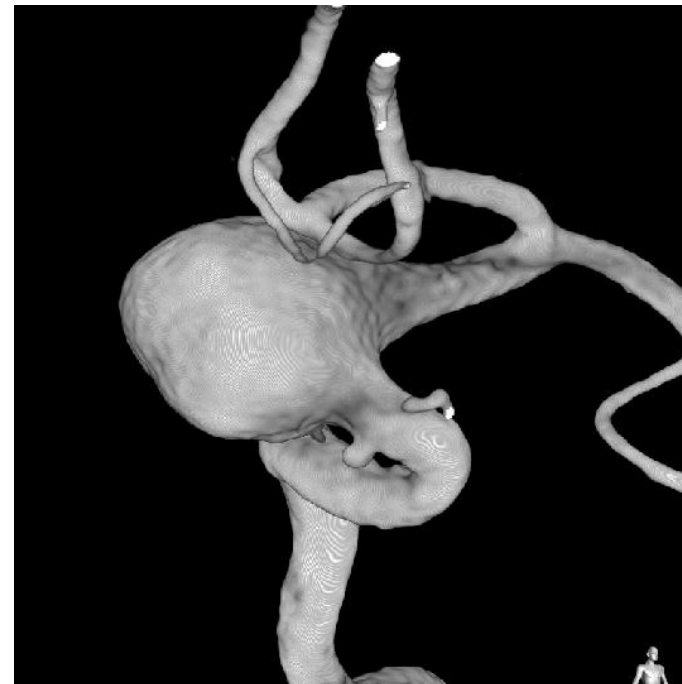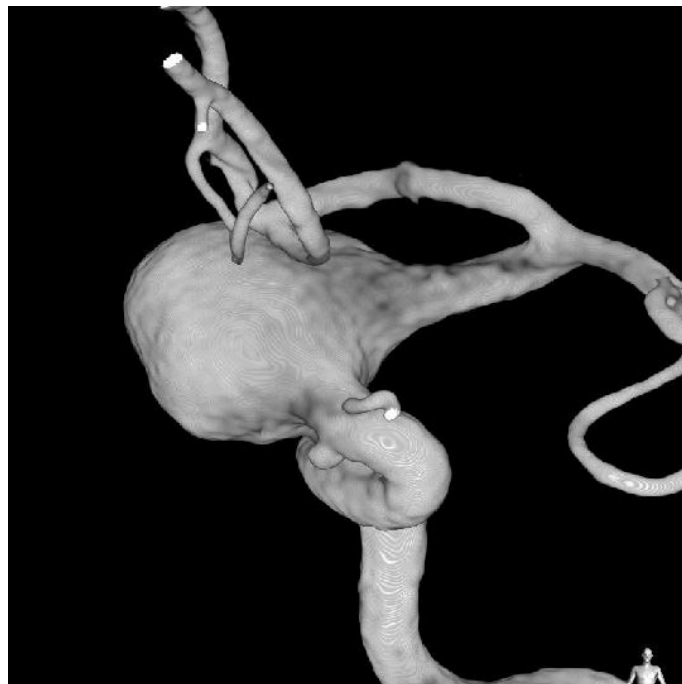
# TOF-MRA



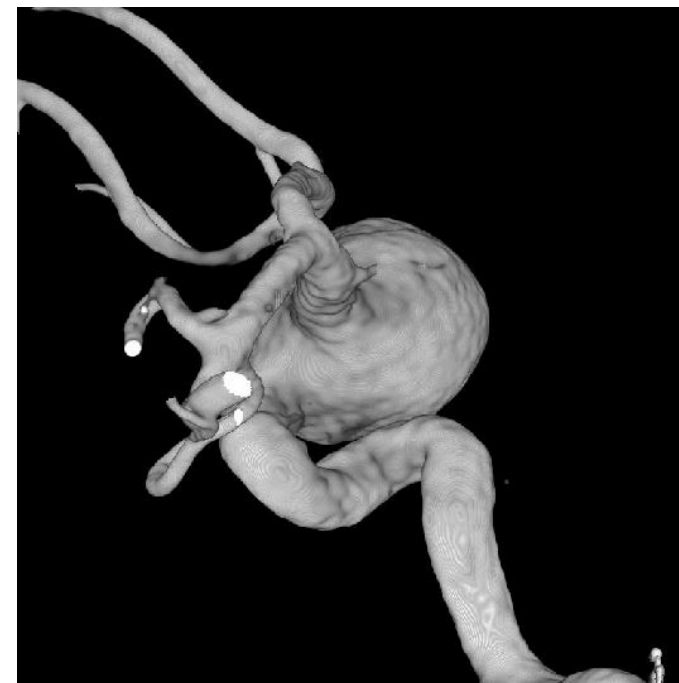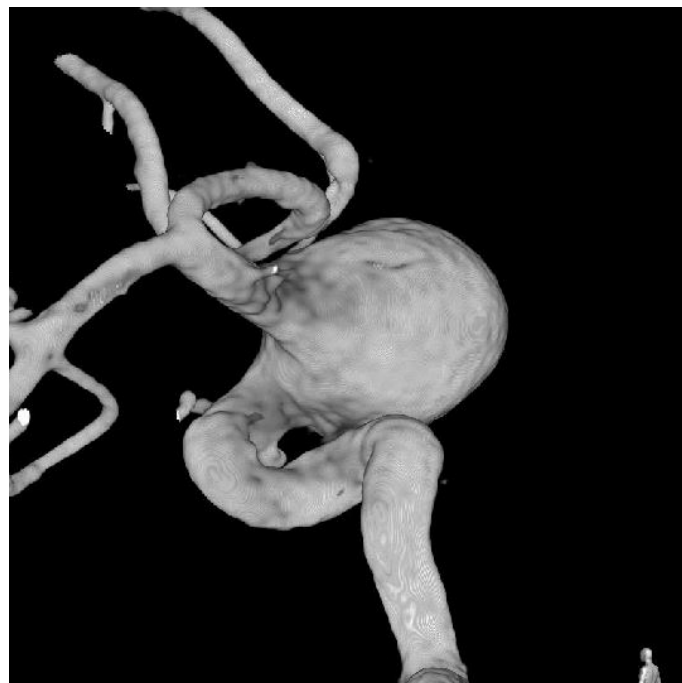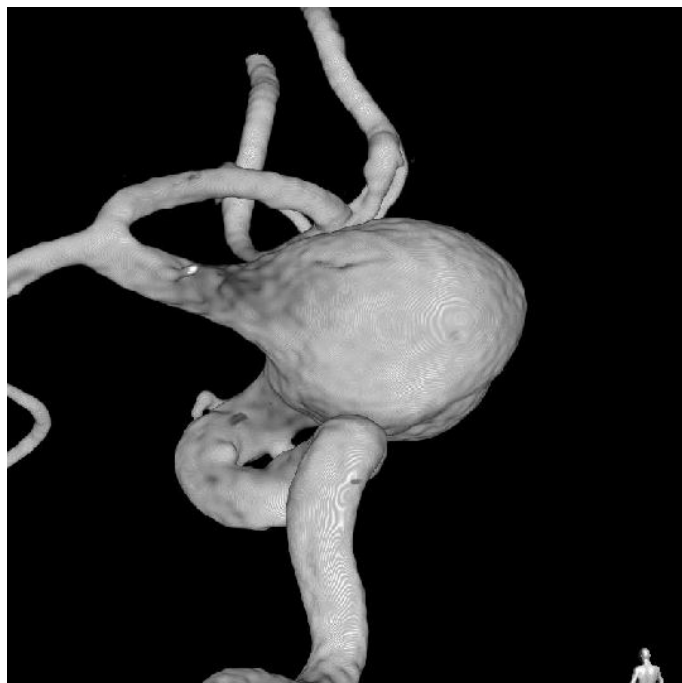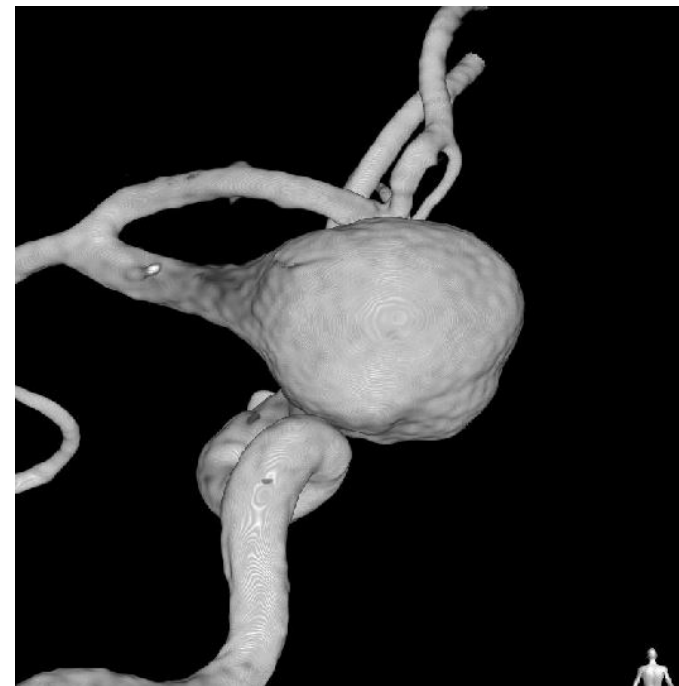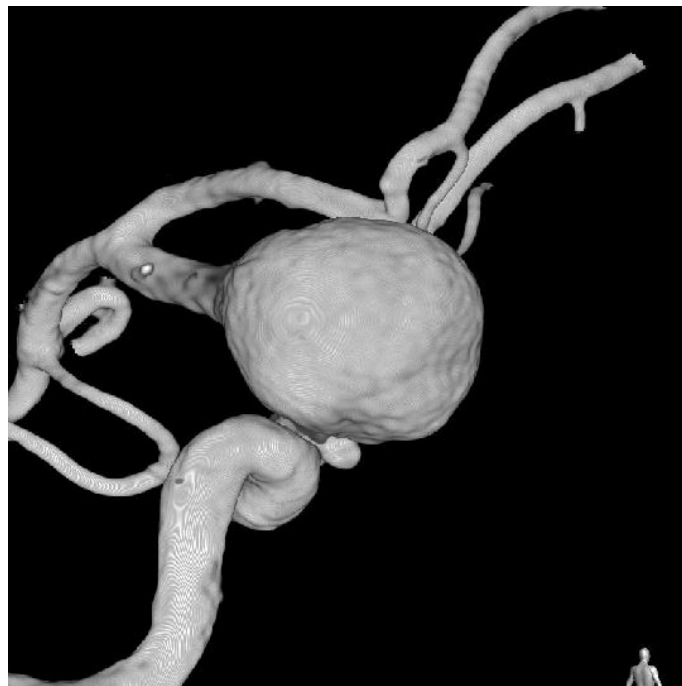Lt. ICAG



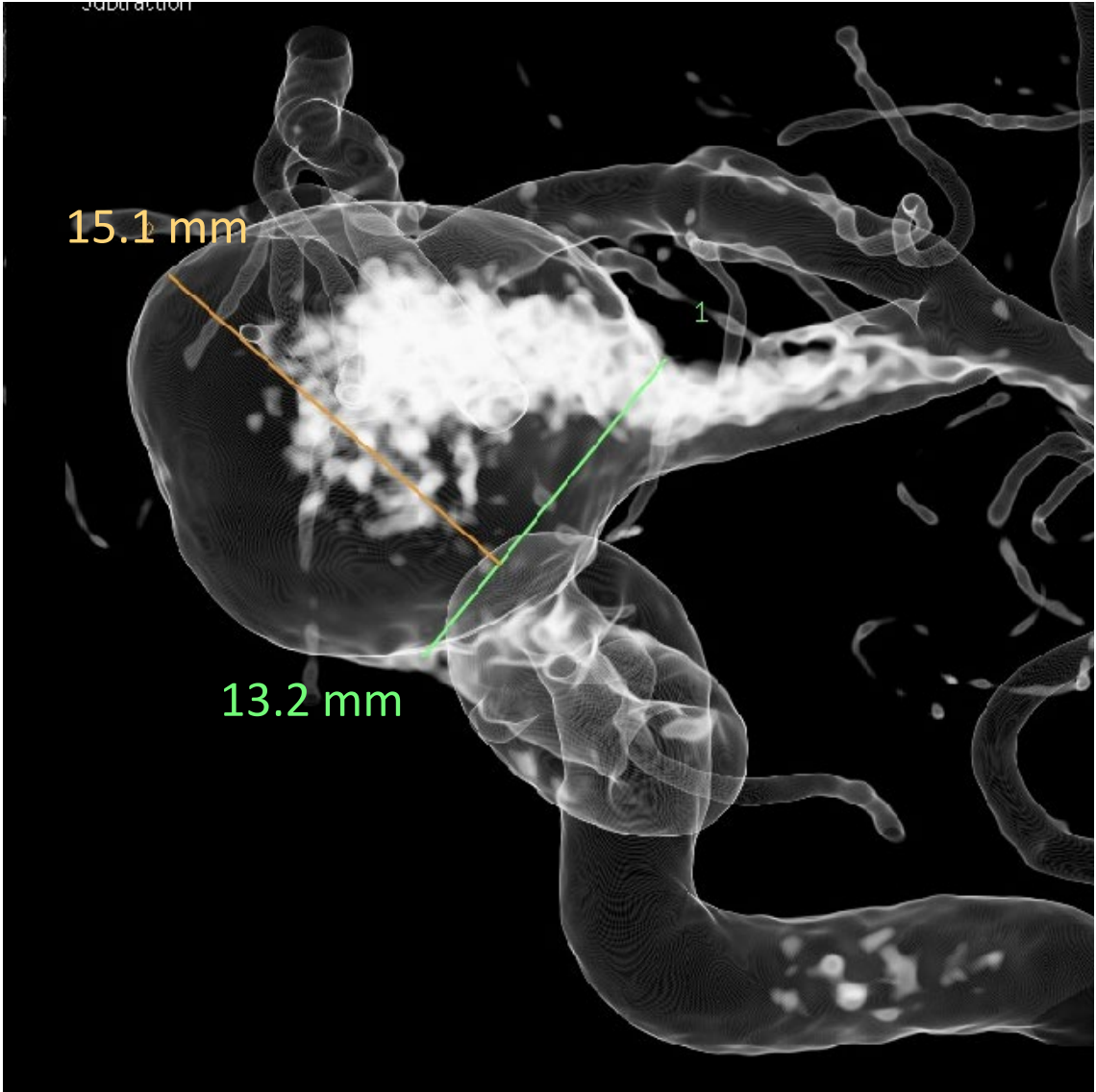
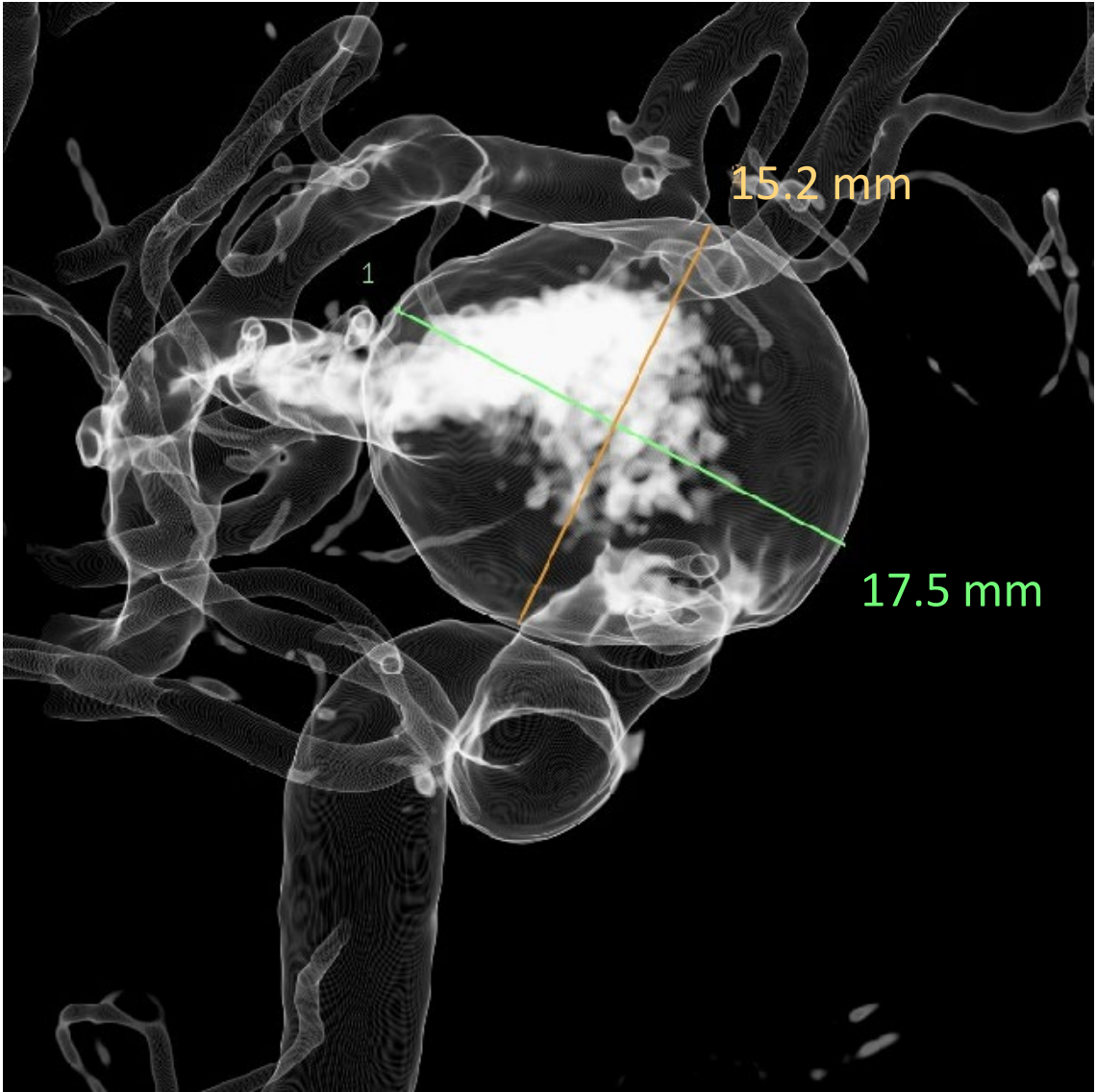
Lt. ICA 3D-RA



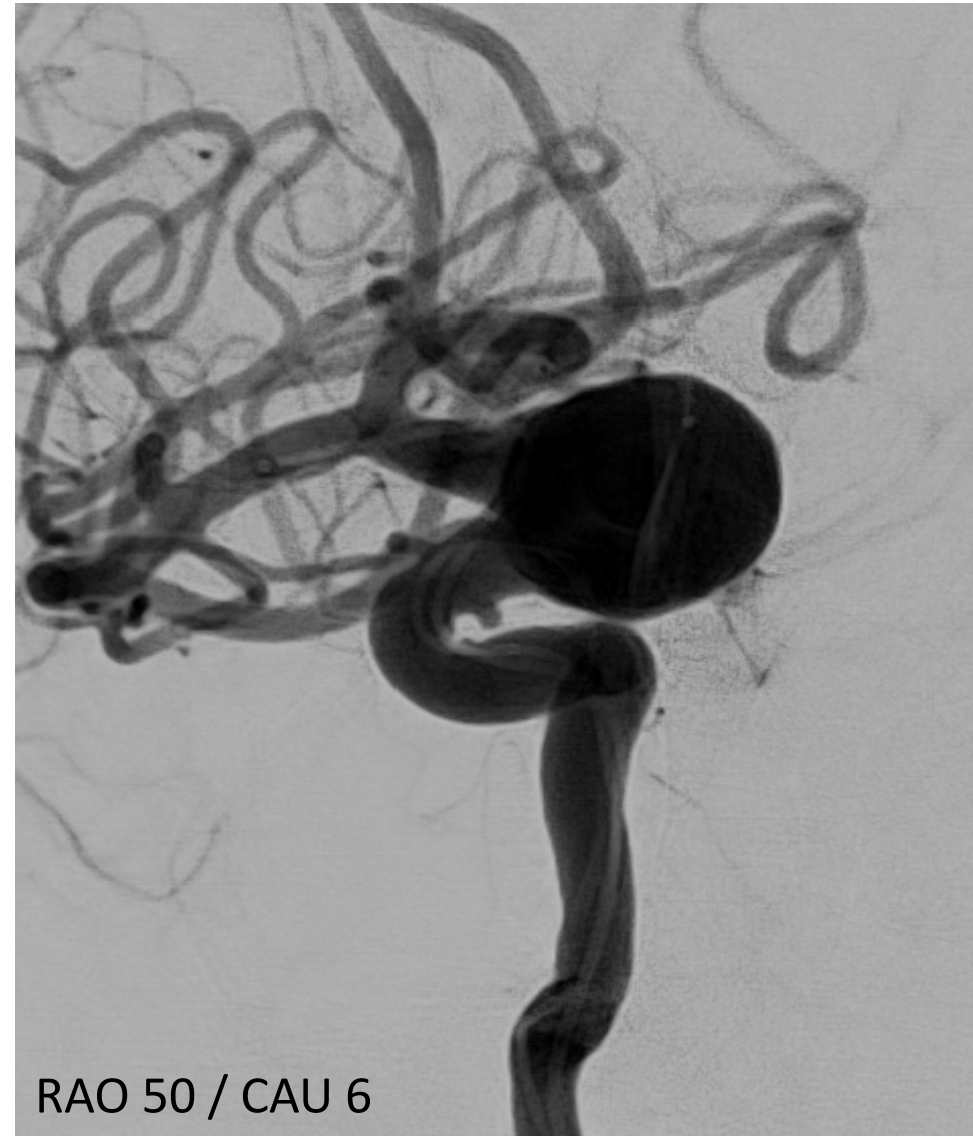
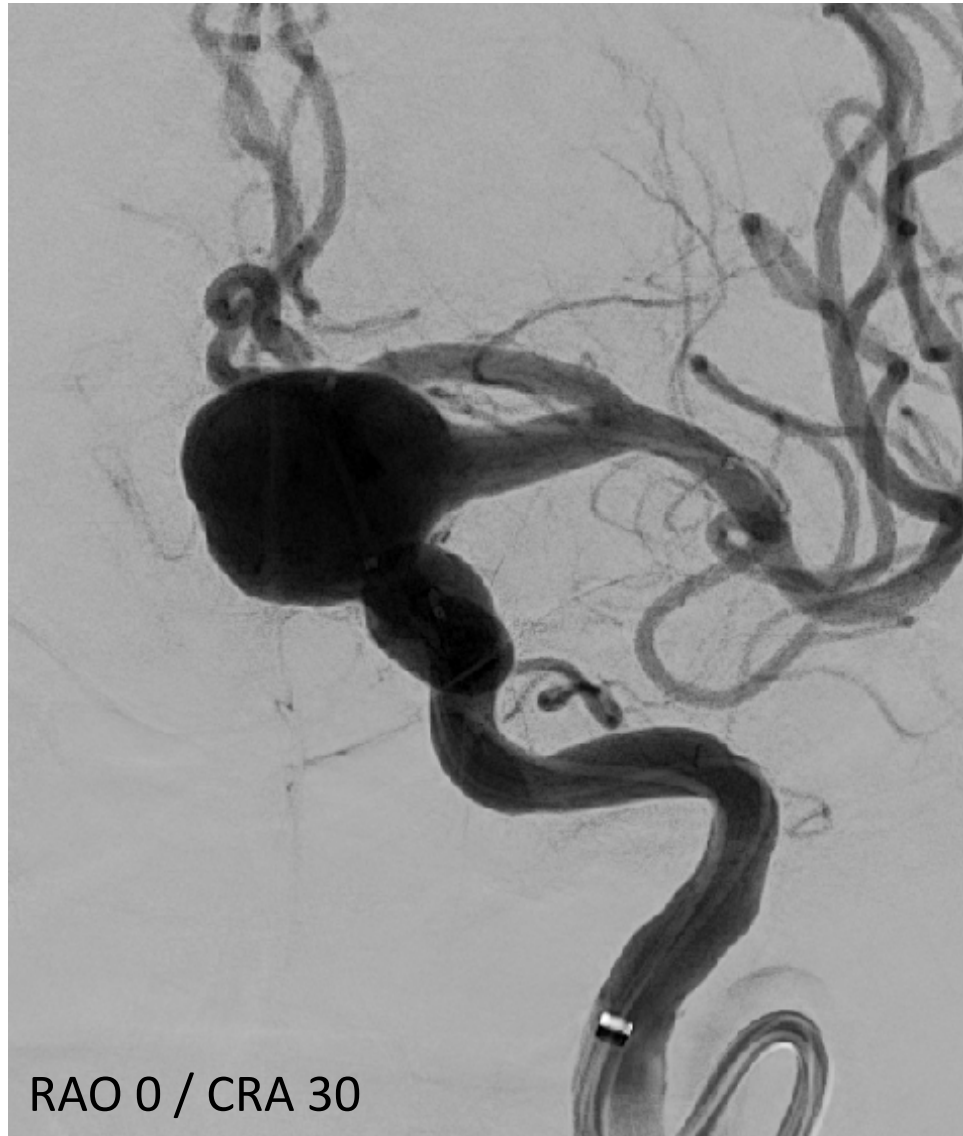
Lt. ICA 3D-RA



Lt. ICA 3D-RA

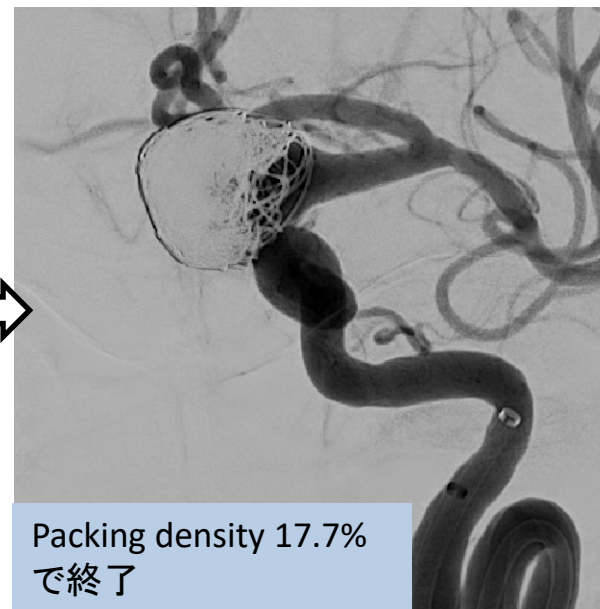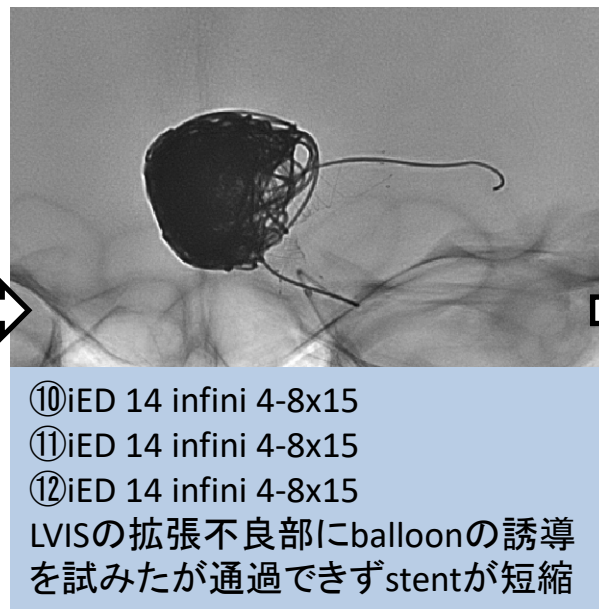
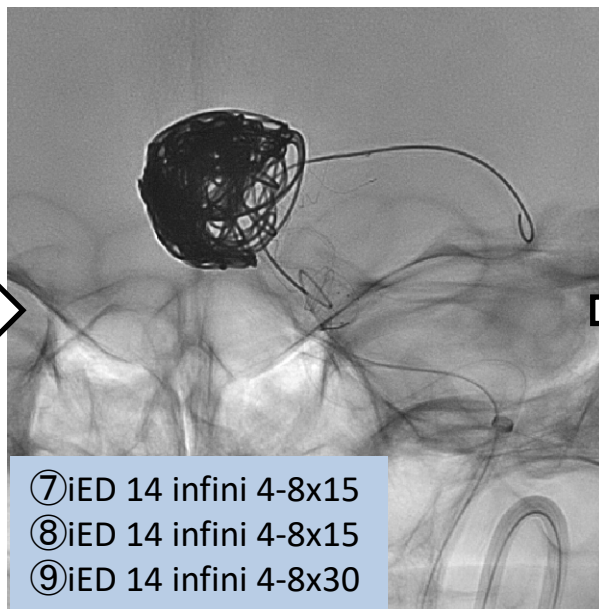
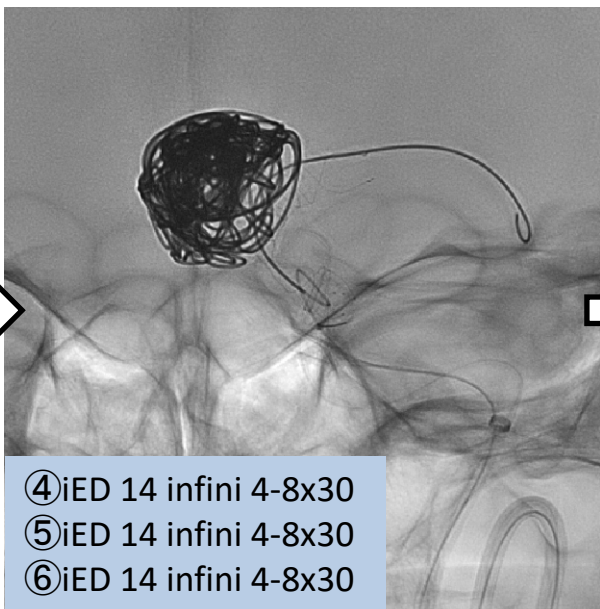
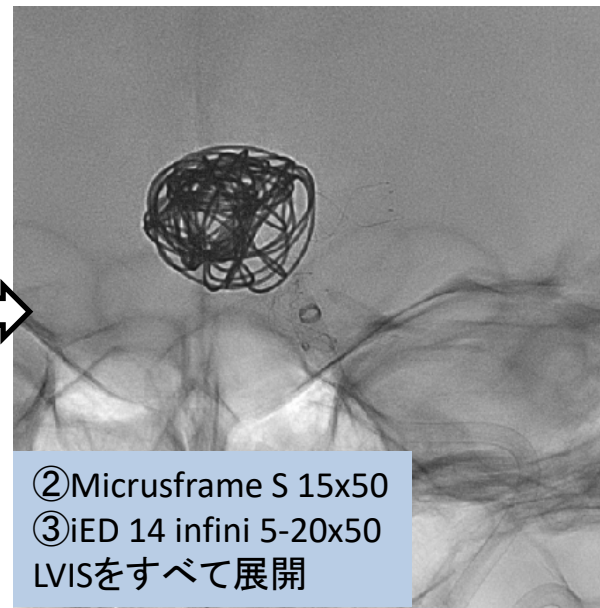
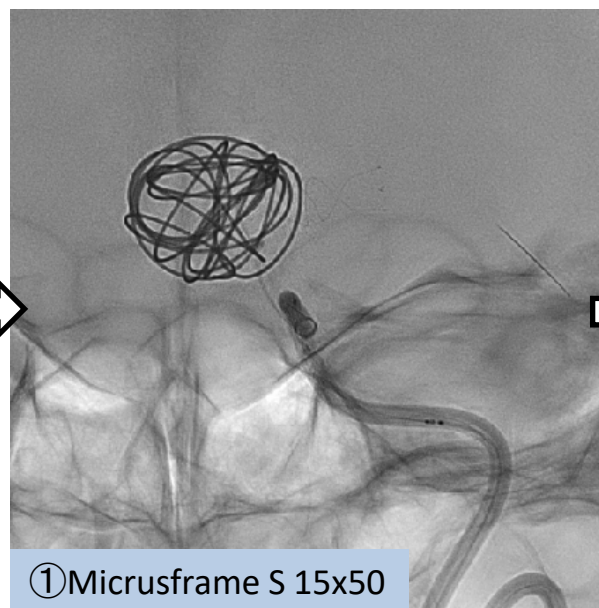
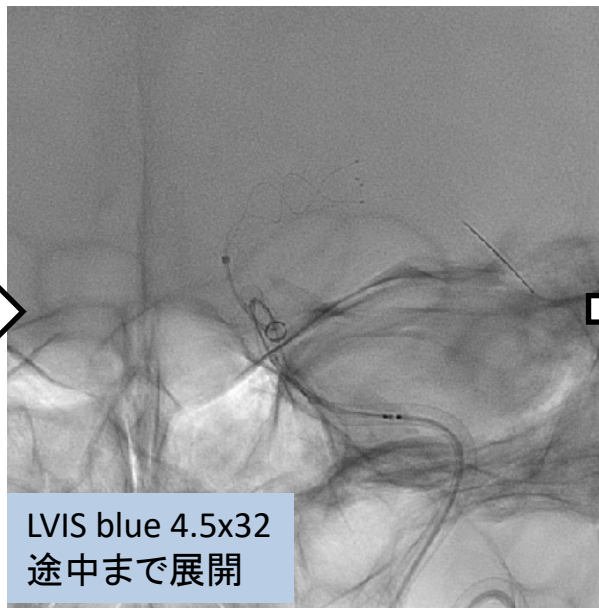
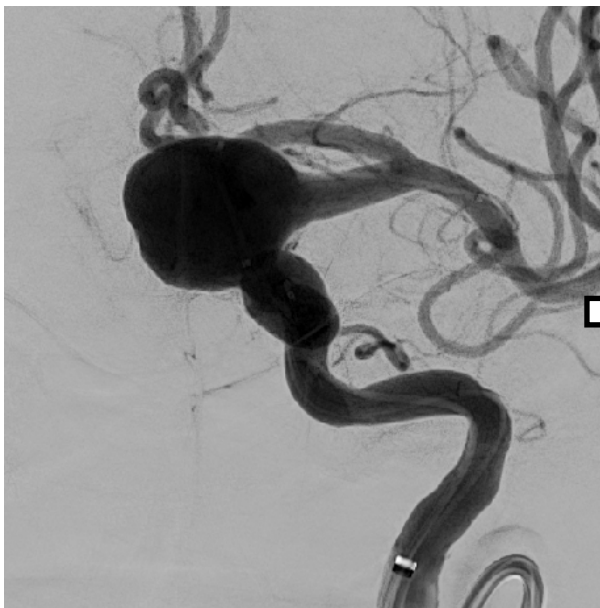


# 初回治療 術前 Lt. ICAG

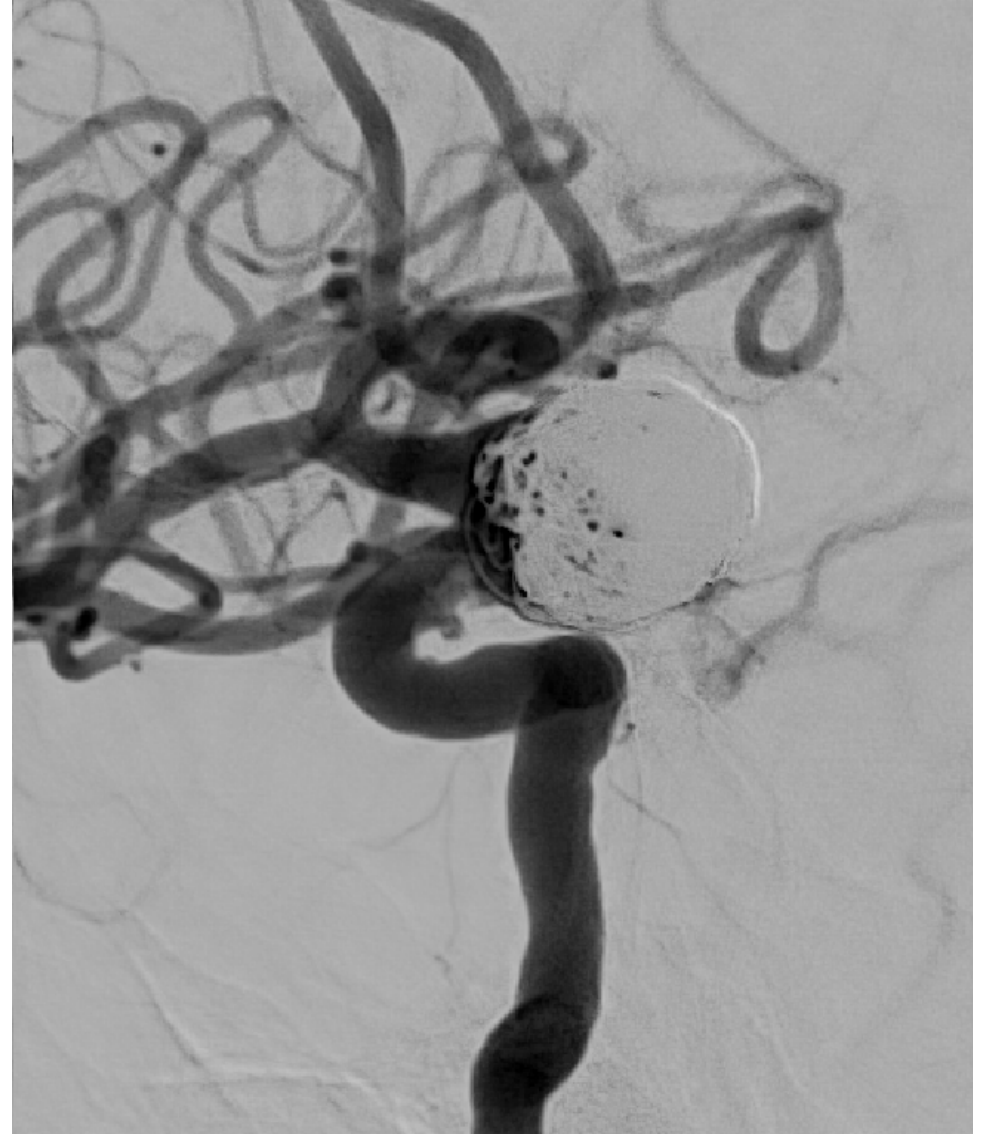
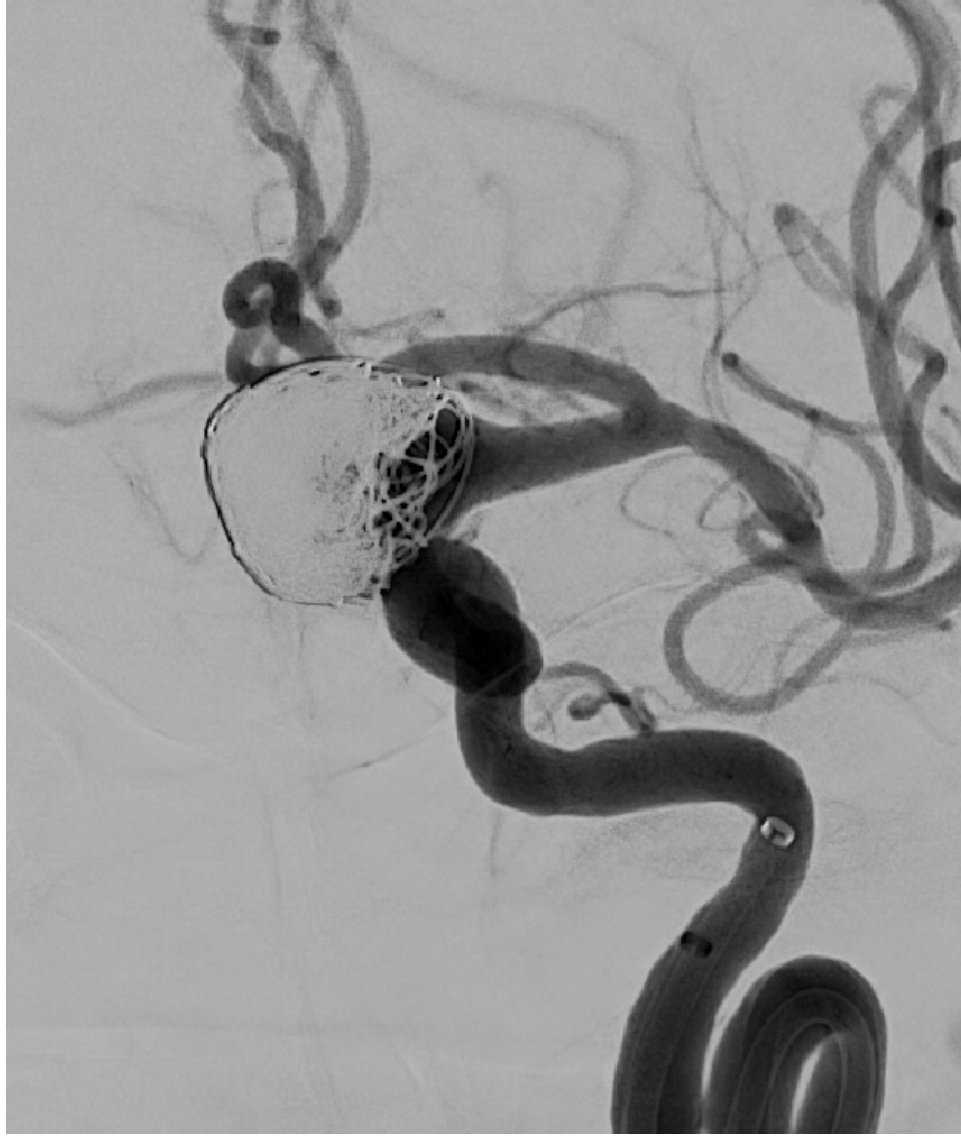




# 初回治療



初回治療 術後 Lt. ICAG

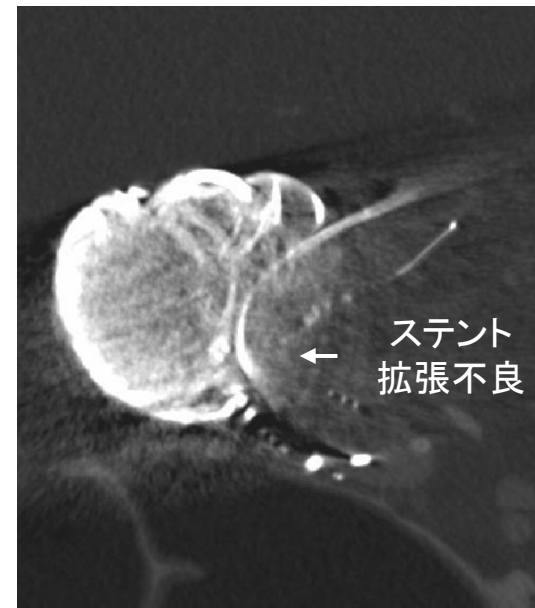
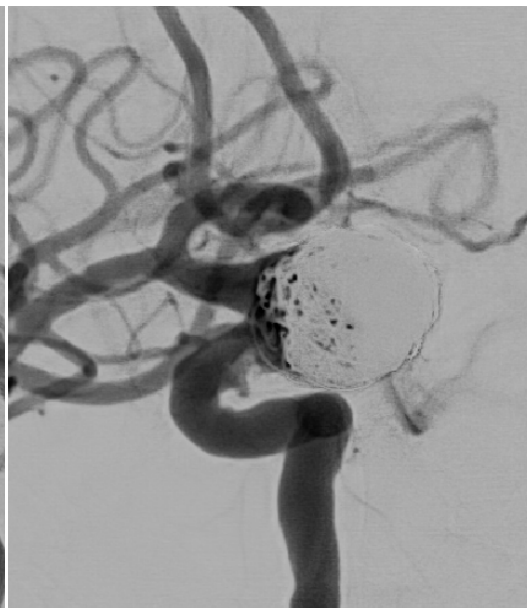
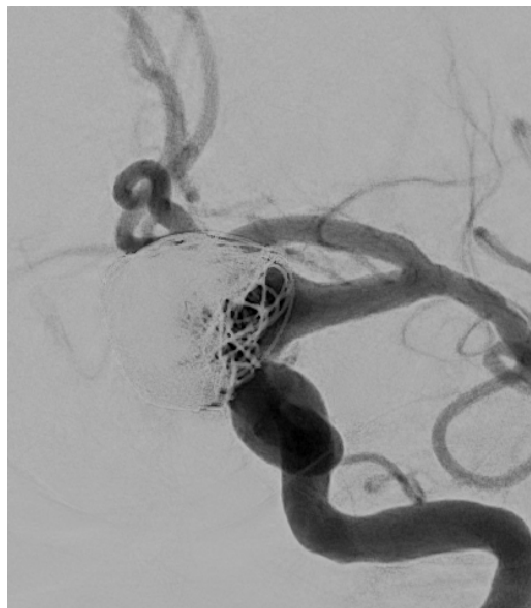
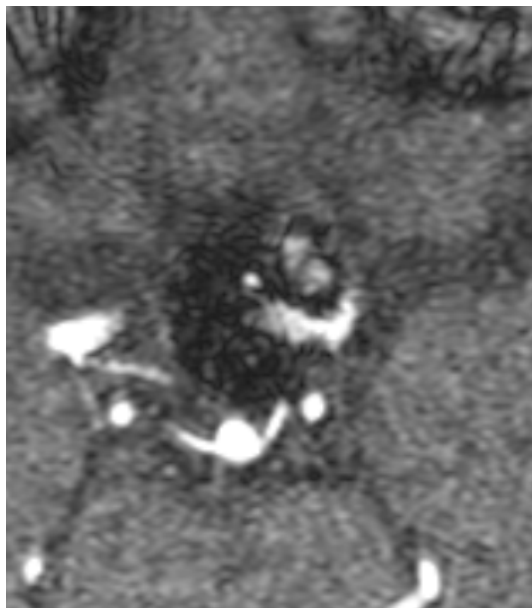

TOF-MRA

Lt. ICAG

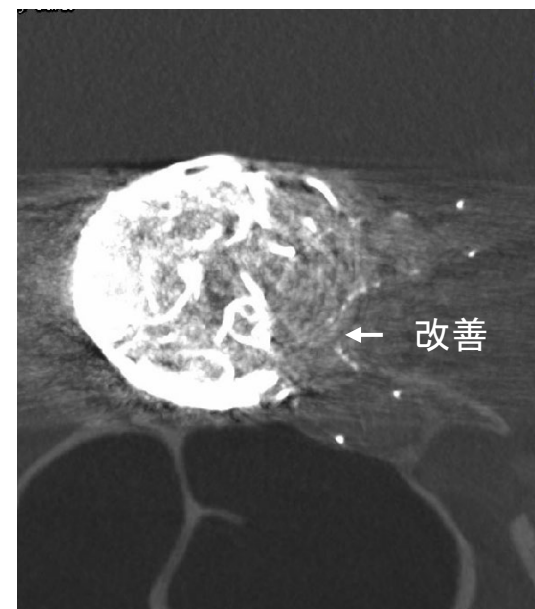
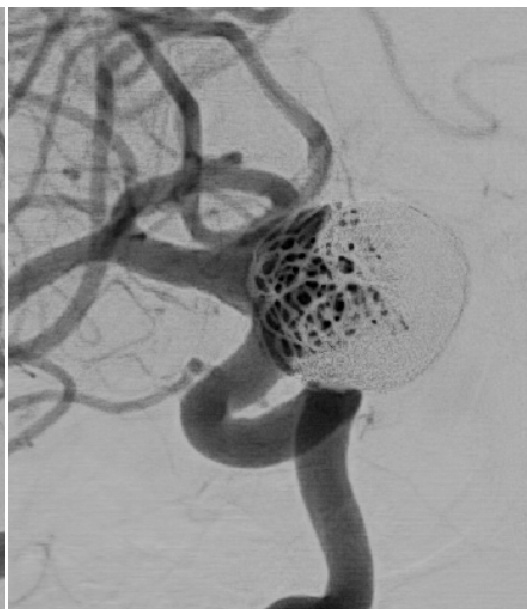
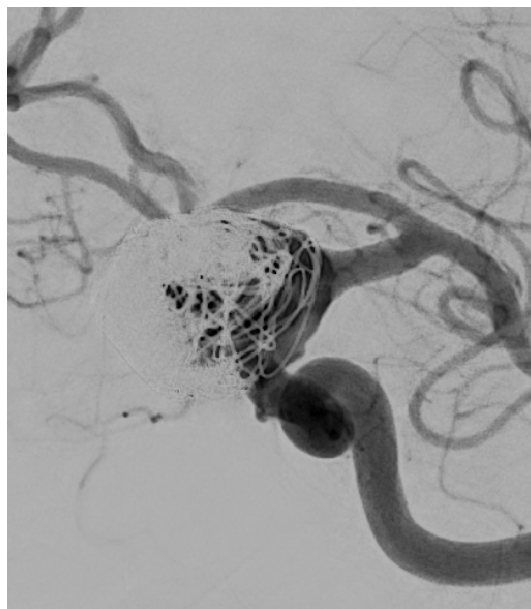
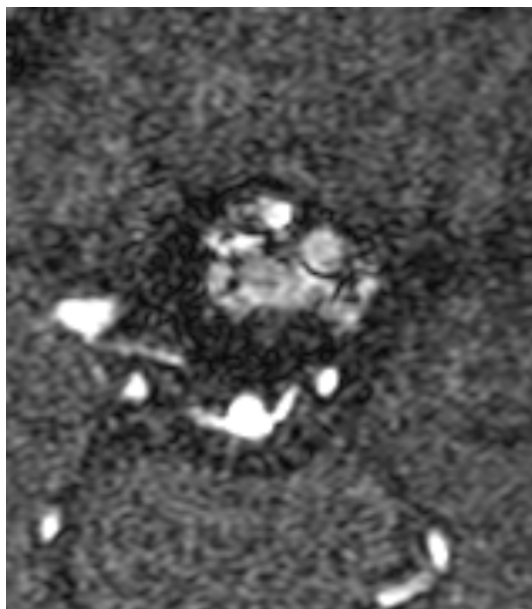
3D-RA Slab MIP

術直後



ステント  
拡張不良

術6ヶ月後



改善

再開通  
やや増大

## Case 01 summary

- ✓ 未破裂大型Paraclinoid 動脈瘤
- ✓ Wide neck、大弯側
- ✓ 再開通、やや増大

## To be discussed...

- ✓ 初回治療はこれでよかったか？
- ✓ 再治療として血管内治療を行うとした場合、用いるテクニックは？
  - ①Simple coiling
  - ②Stent assist (Additional)
  - ③Flow diverter
  - ④その他