

## 症例2

IVR-first方針の施設でclippingを選択した  
「小型IC-PC動脈瘤（+ACoA瘤）」

# 77歳女性

【既往歴】 高血圧症

【家族歴】 娘：椎骨動脈解離（当科通院中）

【現病歴】

右難聴の精査目的にMRI/MRA施行され、多発脳動脈瘤を指摘

【身体所見】

意識清明

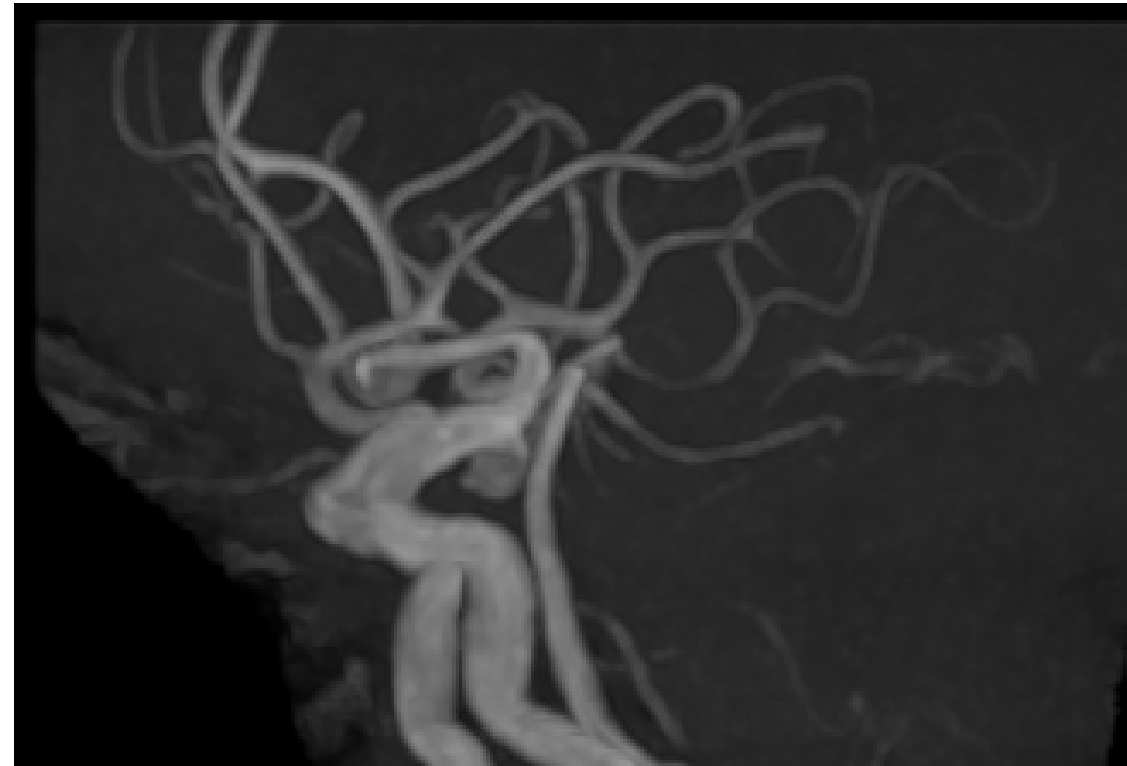
右張力低下以外に神経学的異常なし

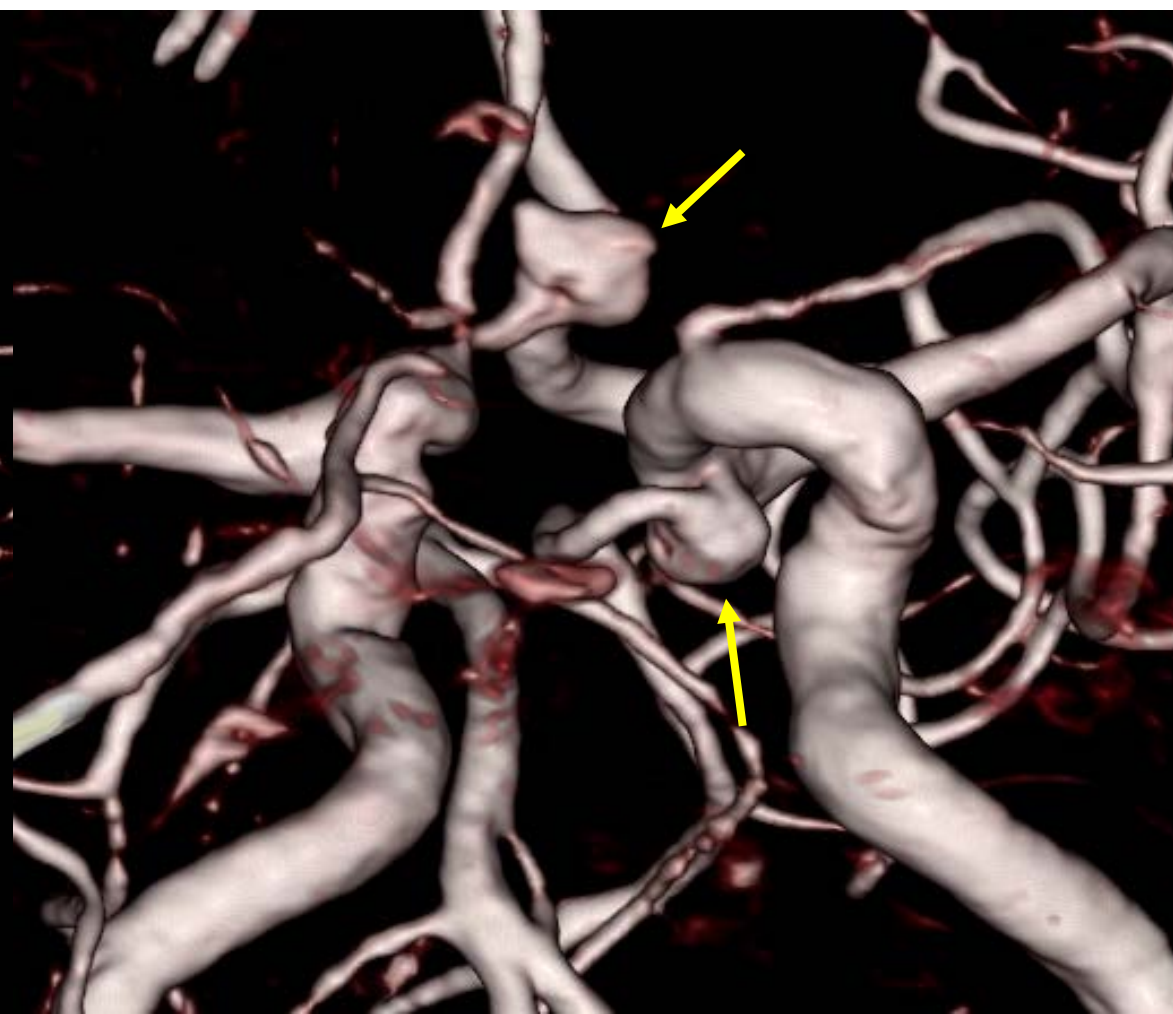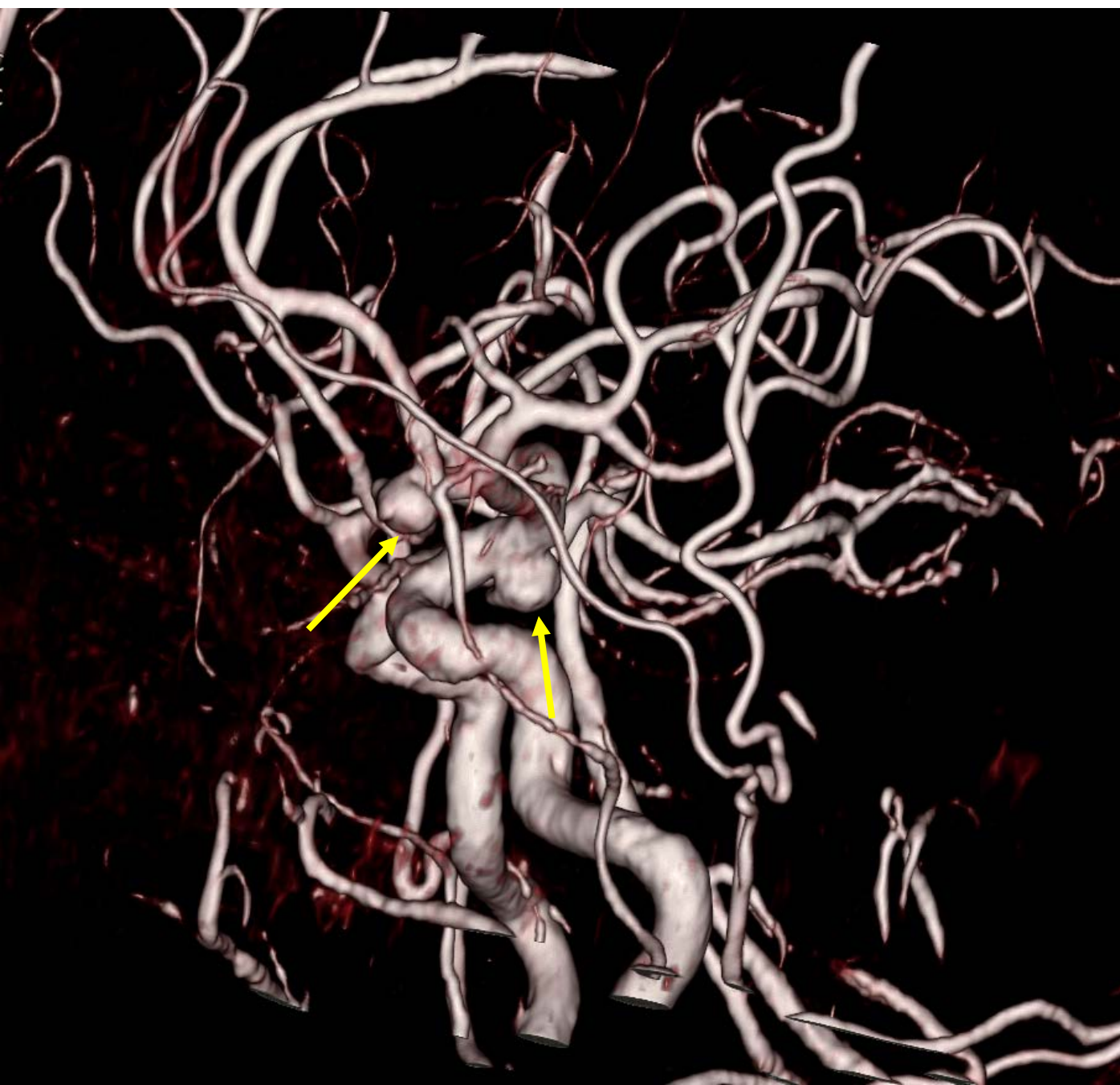
HDS-R 23点

【全身所見】

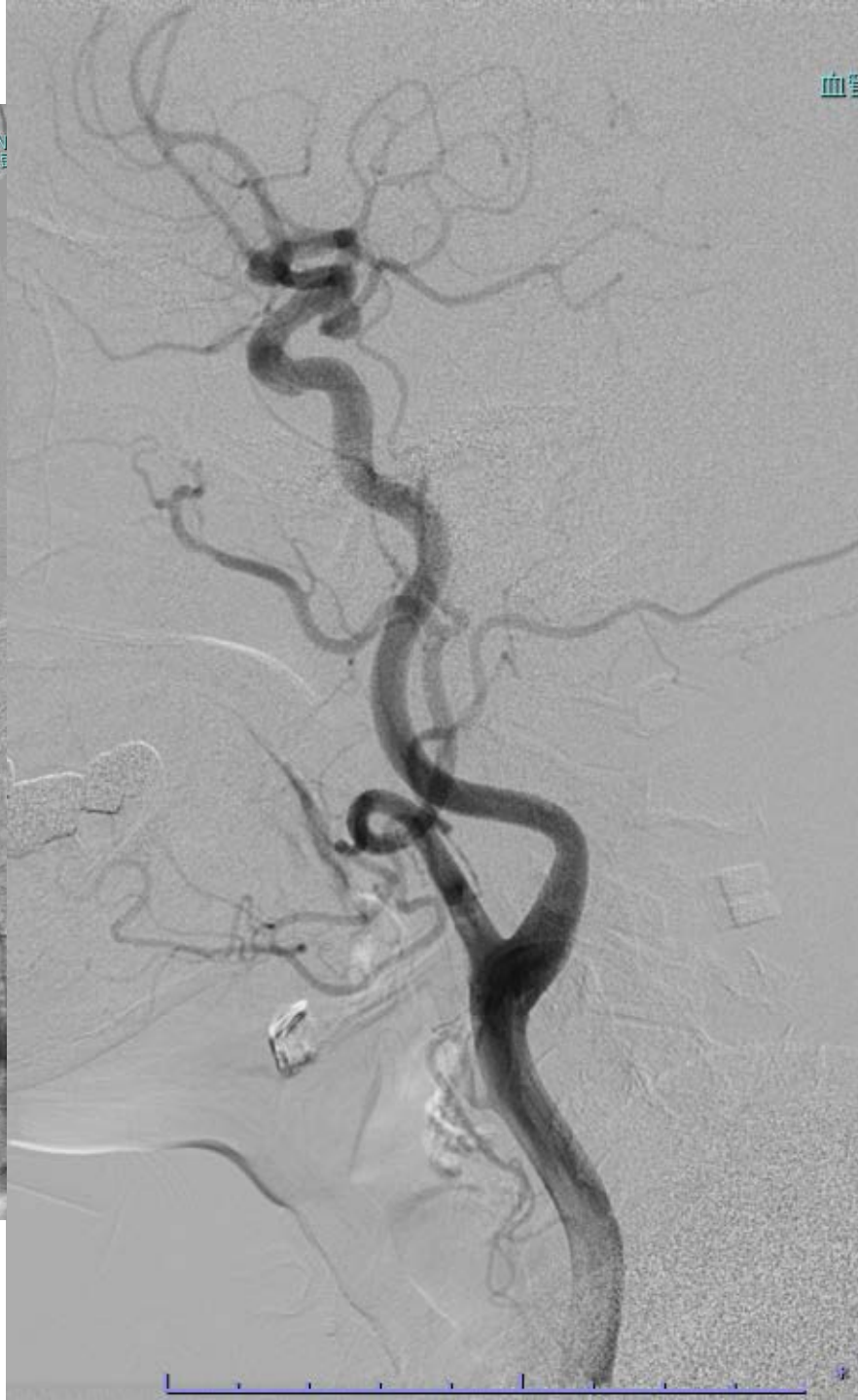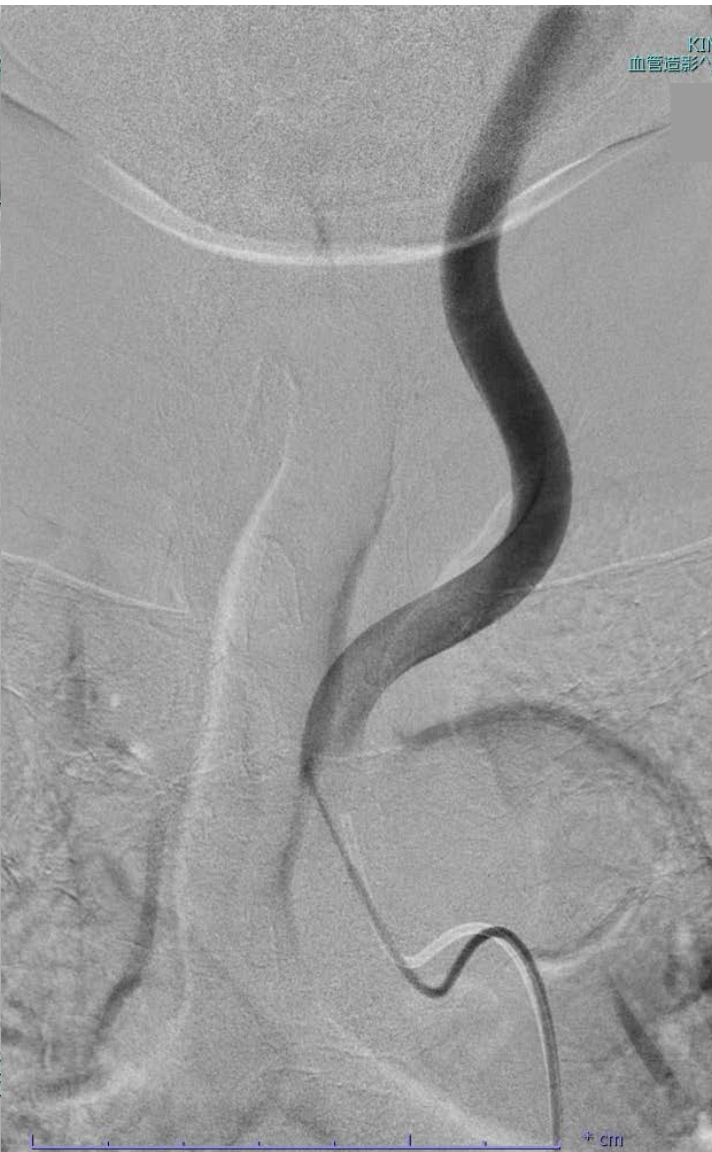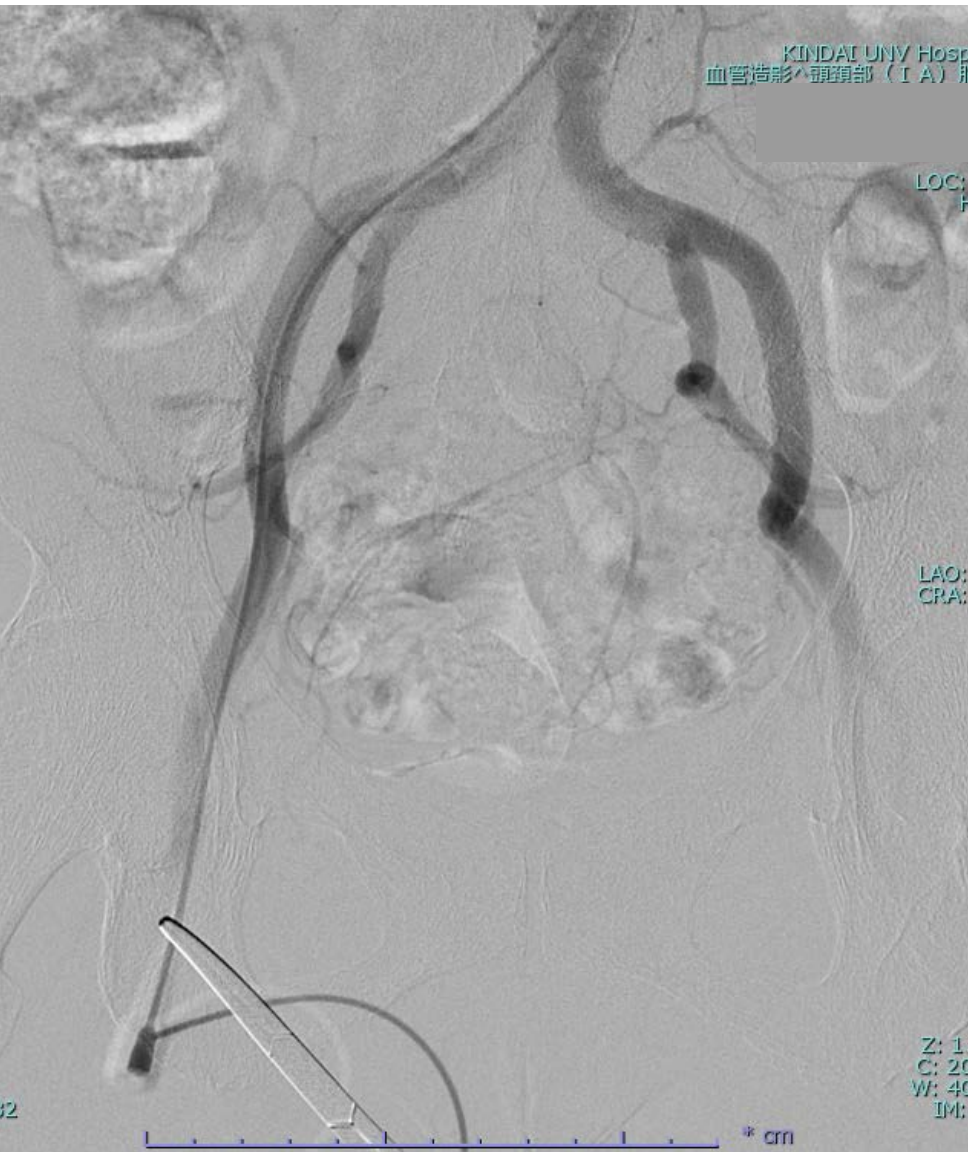心エコー：正常

呼吸機能検査：正常





MRA 3D再構成



LOC: ---  
HFS

LAO: 95  
CRA: 2

Z: 1.0  
C: 2048  
W: 4096  
IM: 14

\* cm

LOC: ---  
HFS

LAO: 0  
CRA: 20

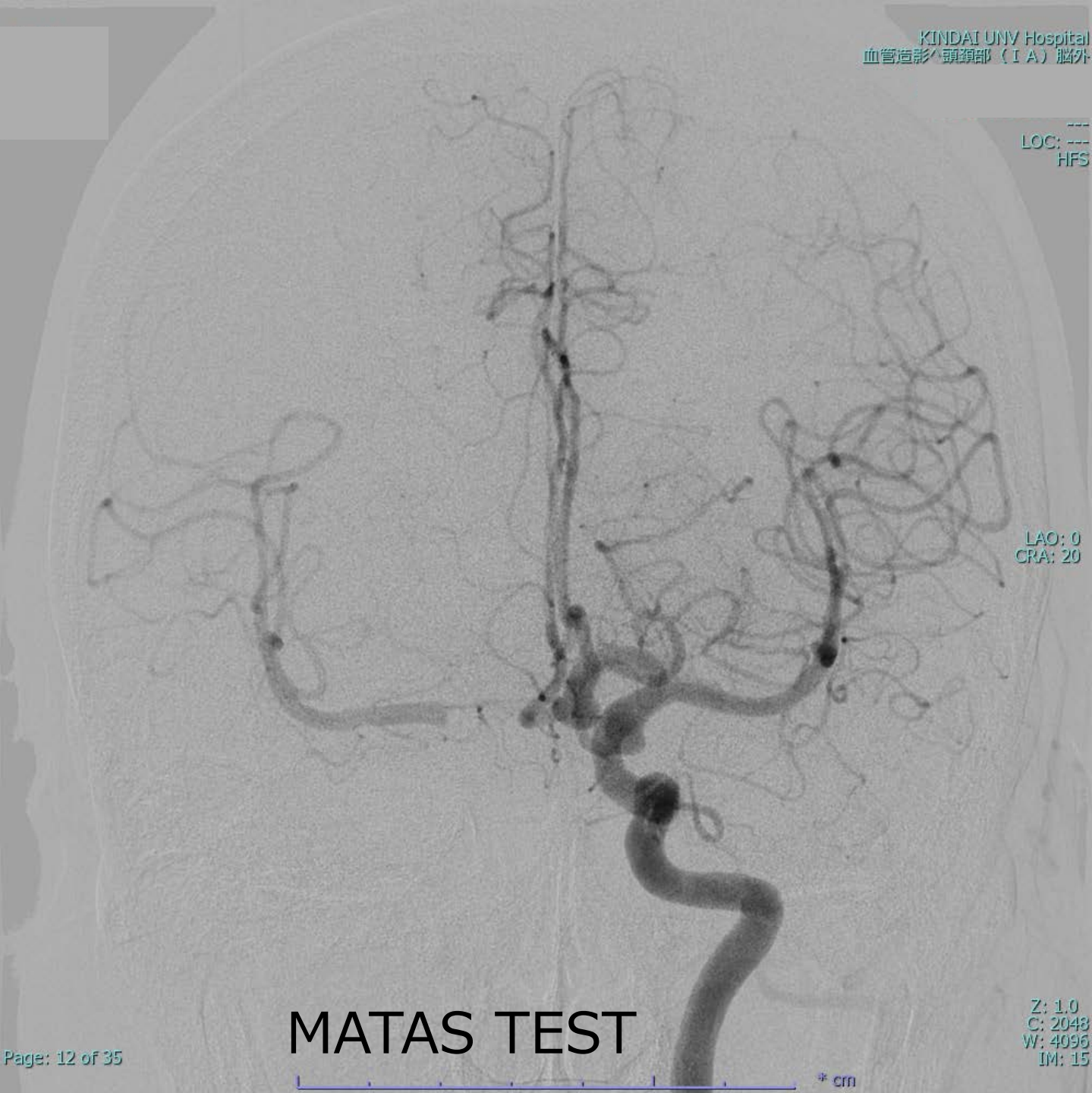
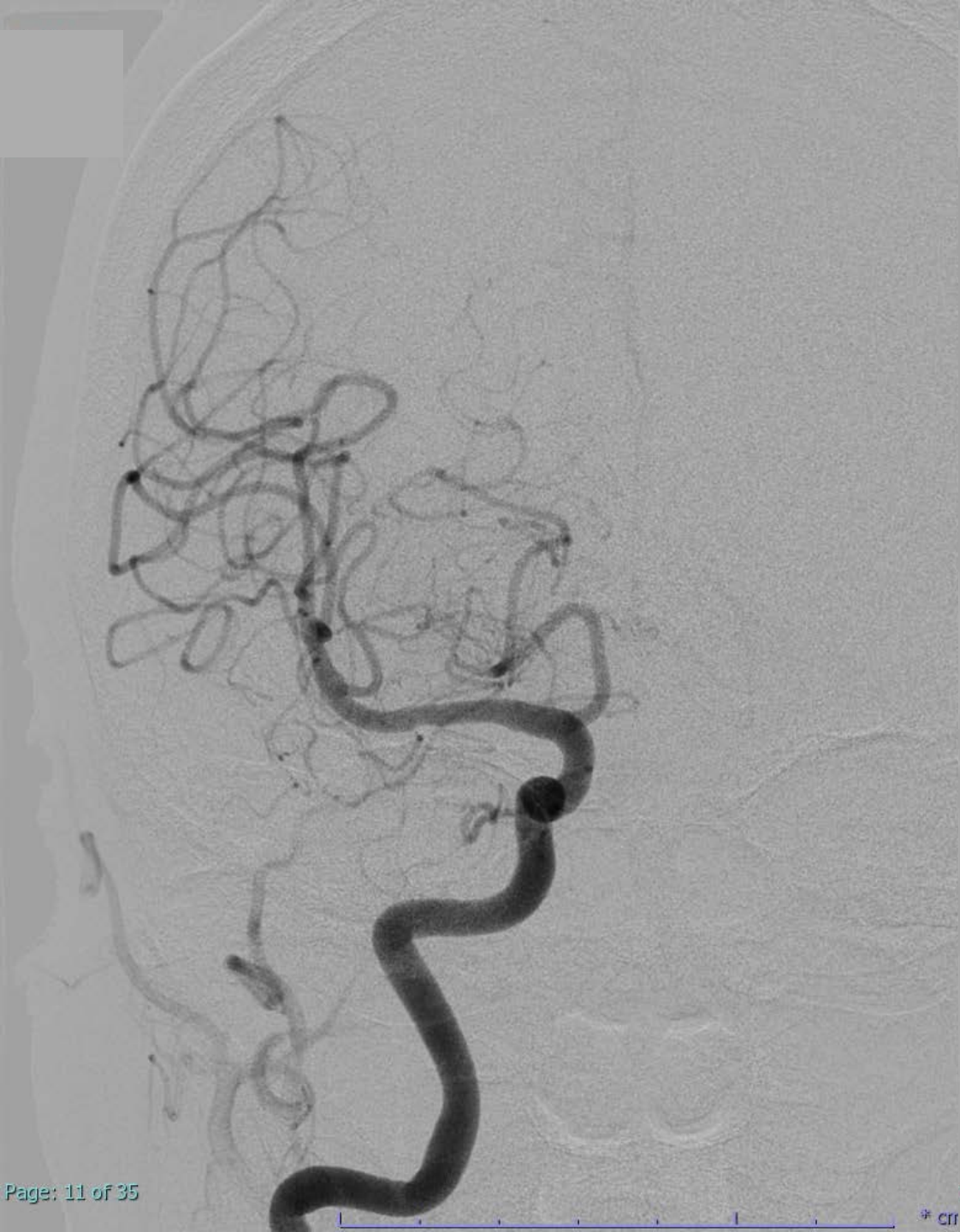
Z: 1.0  
C: 2048  
W: 4096  
IM: 15

\* cm

LOC: ---  
HFS

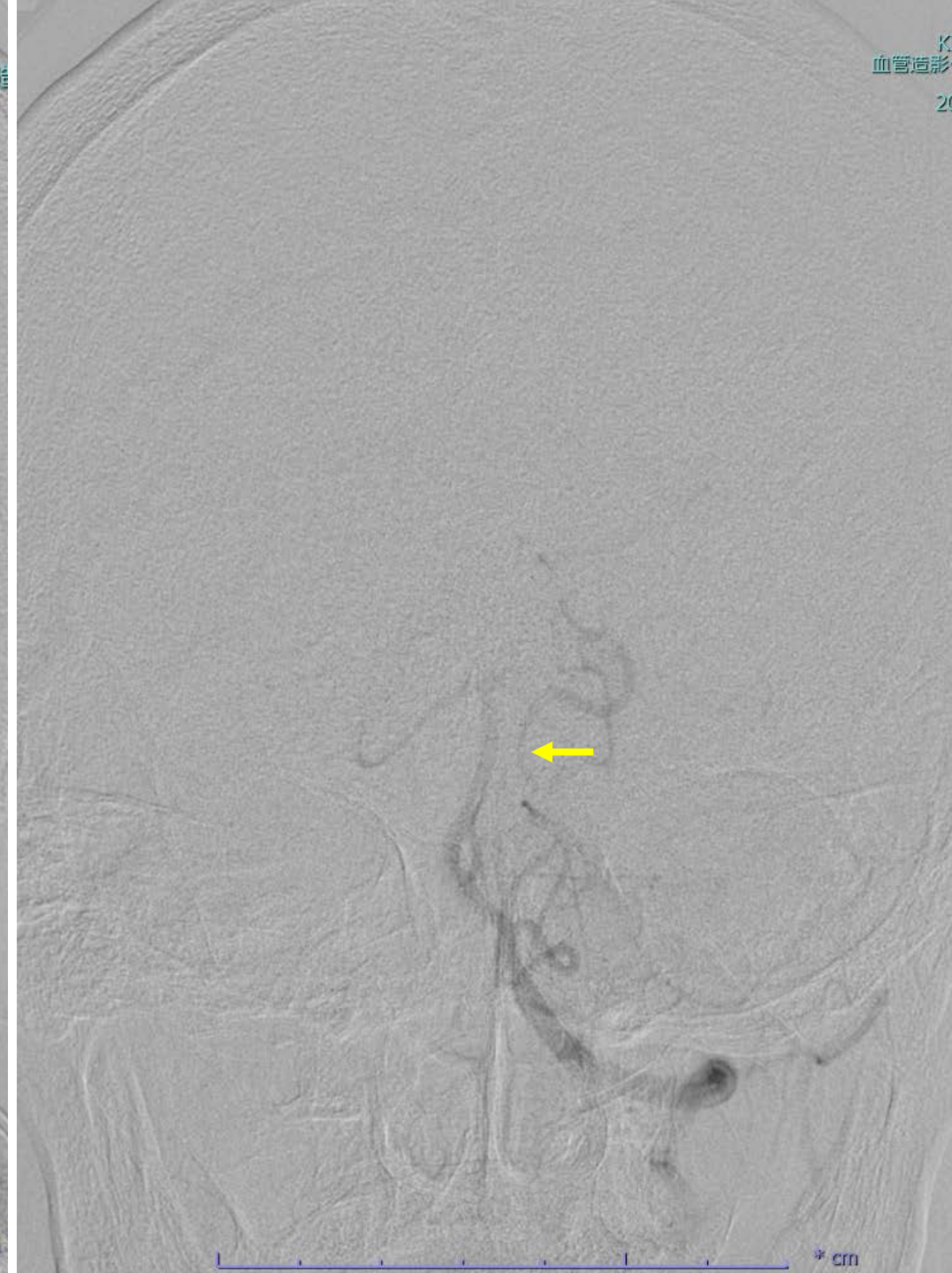
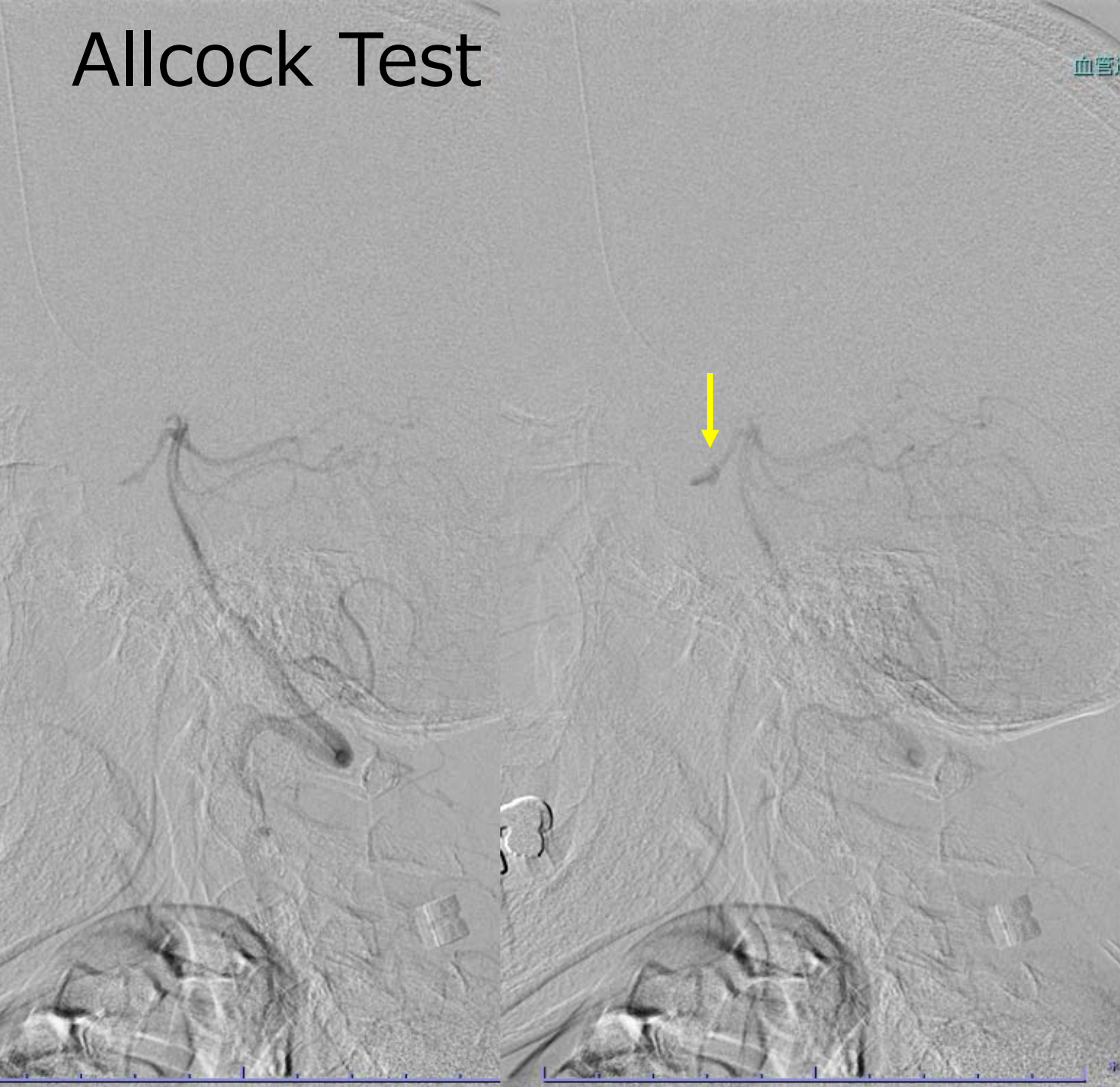
LAO: 0  
CRA: 20

Z: 1.0  
C: 2048  
W: 4096  
IM: 15



MATAS TEST

# Allcock Test



Volume Rendering No cut

DFOV 8.7 x 7.9 cm

No Filter

R  
A

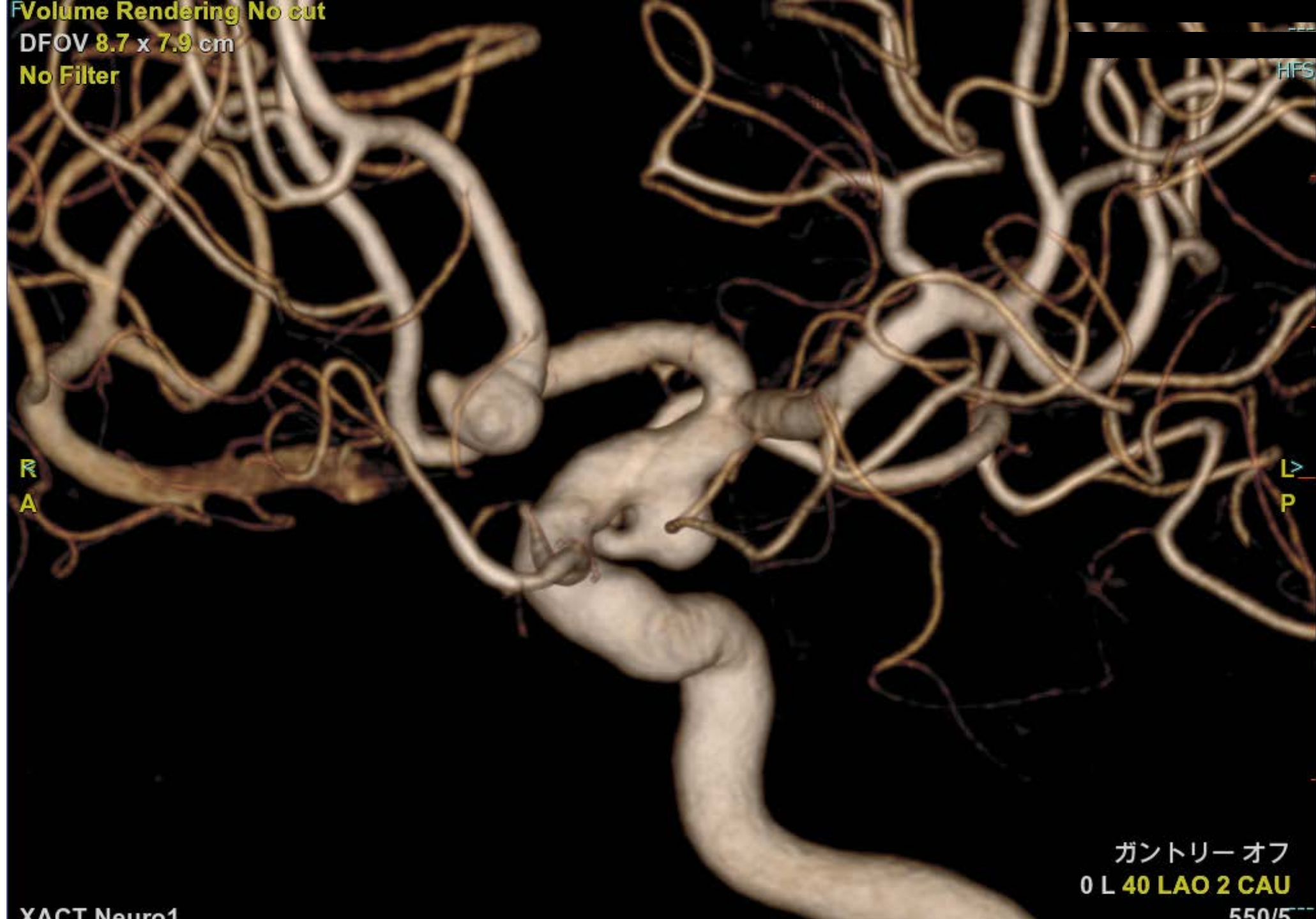L  
P

HFS

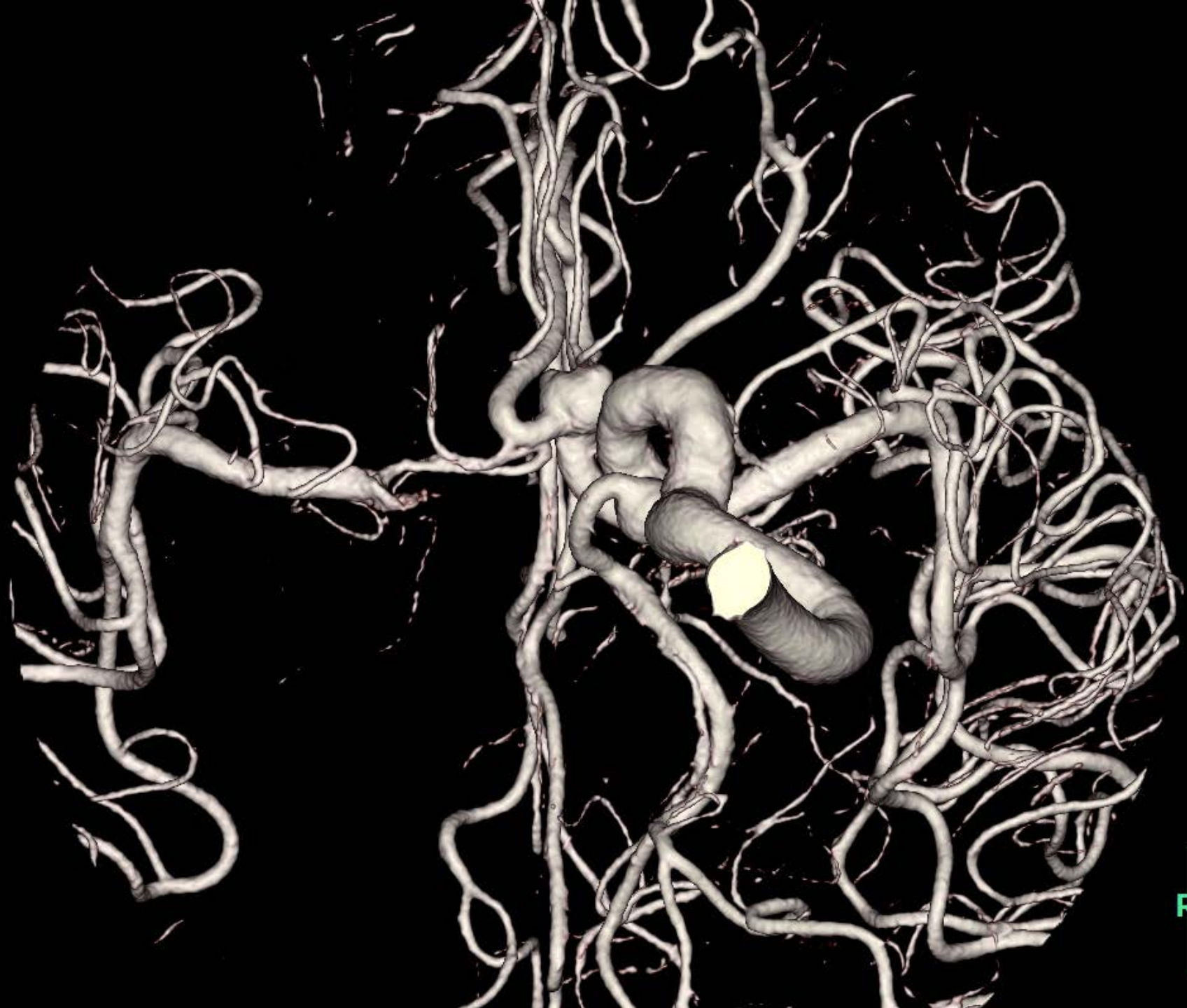ガントリー オフ  
0 L 40 LAO 2 CAU

550/5


XACT Neuro1

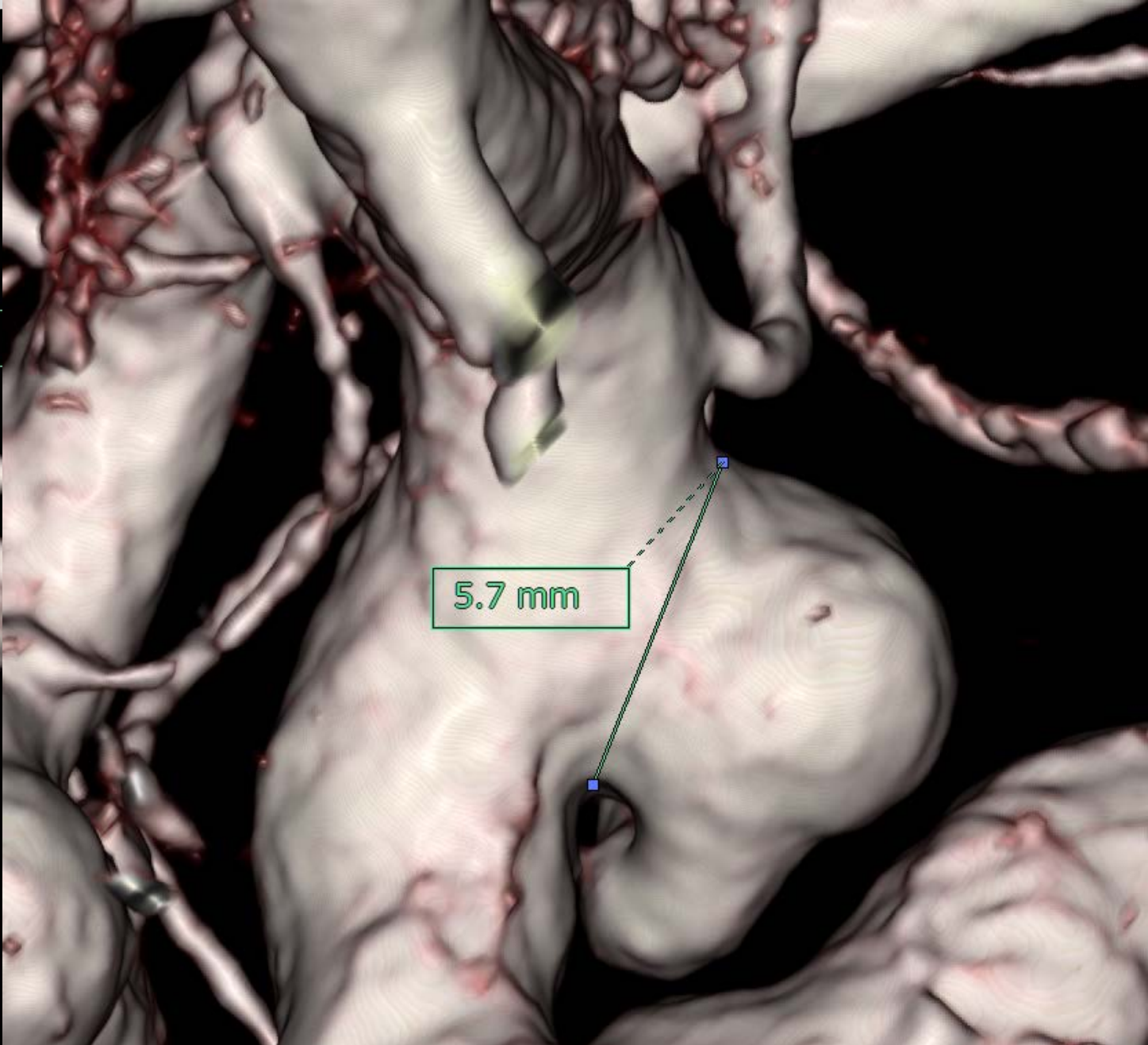
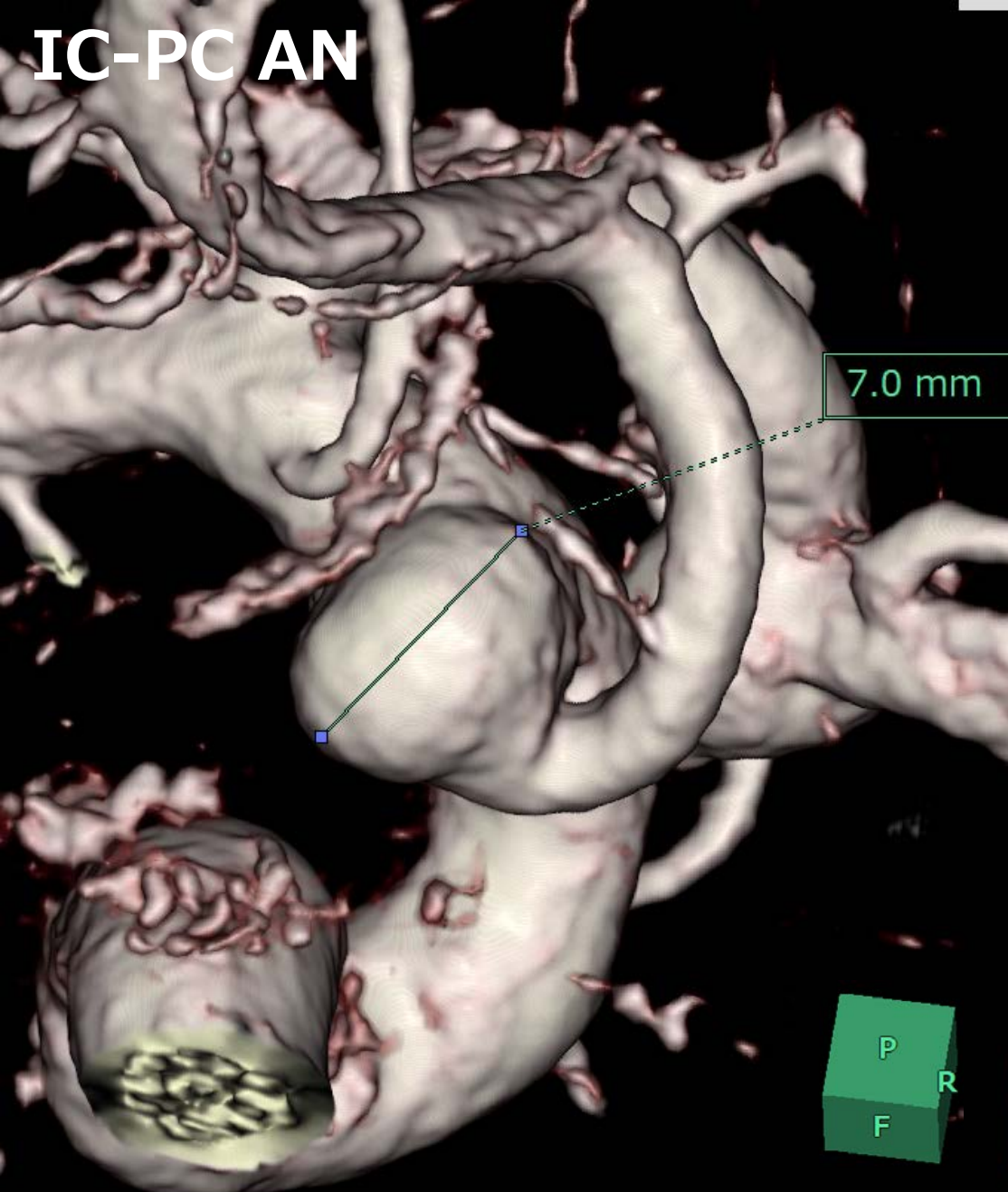


Se:



10 mm/cm

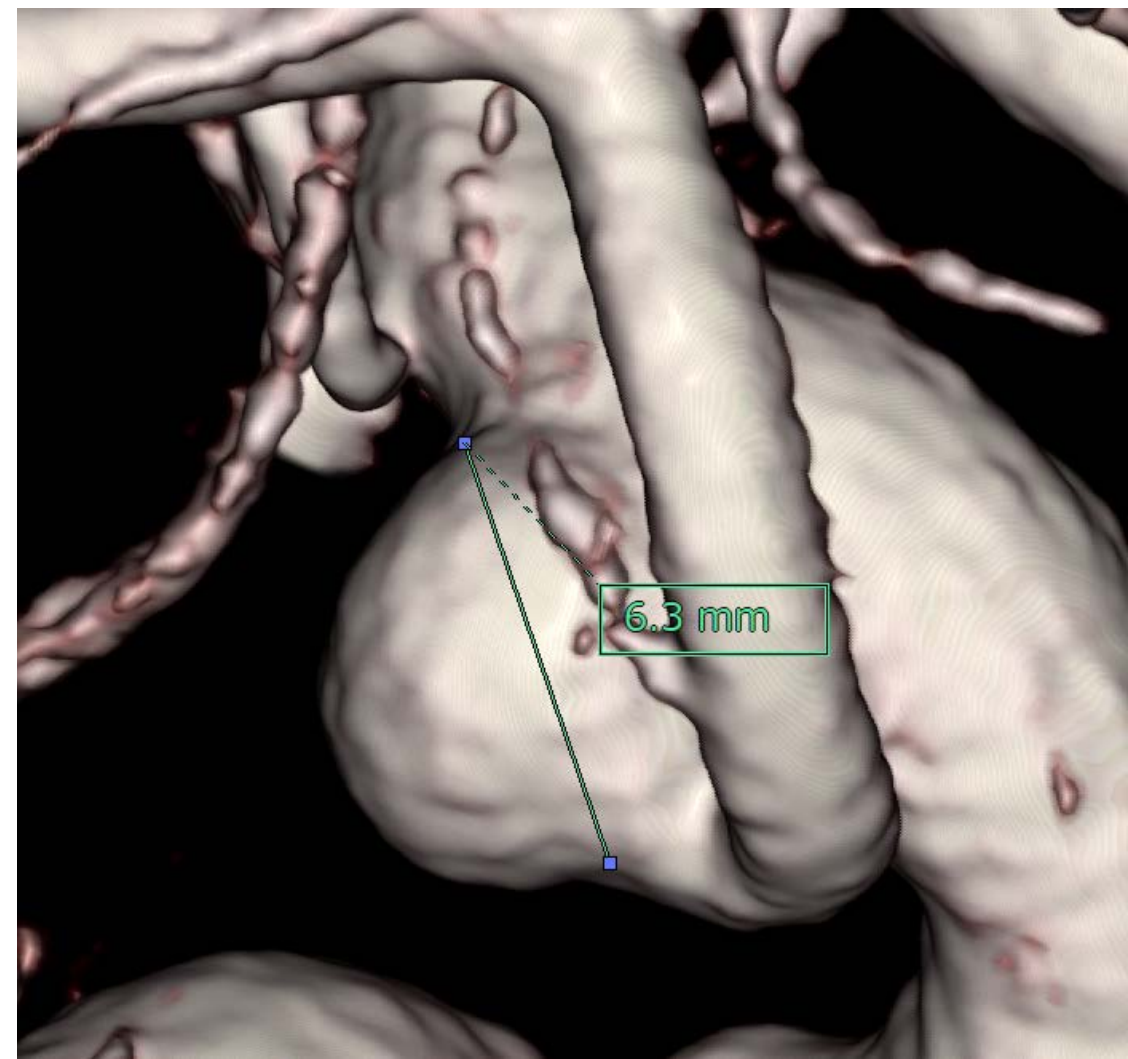
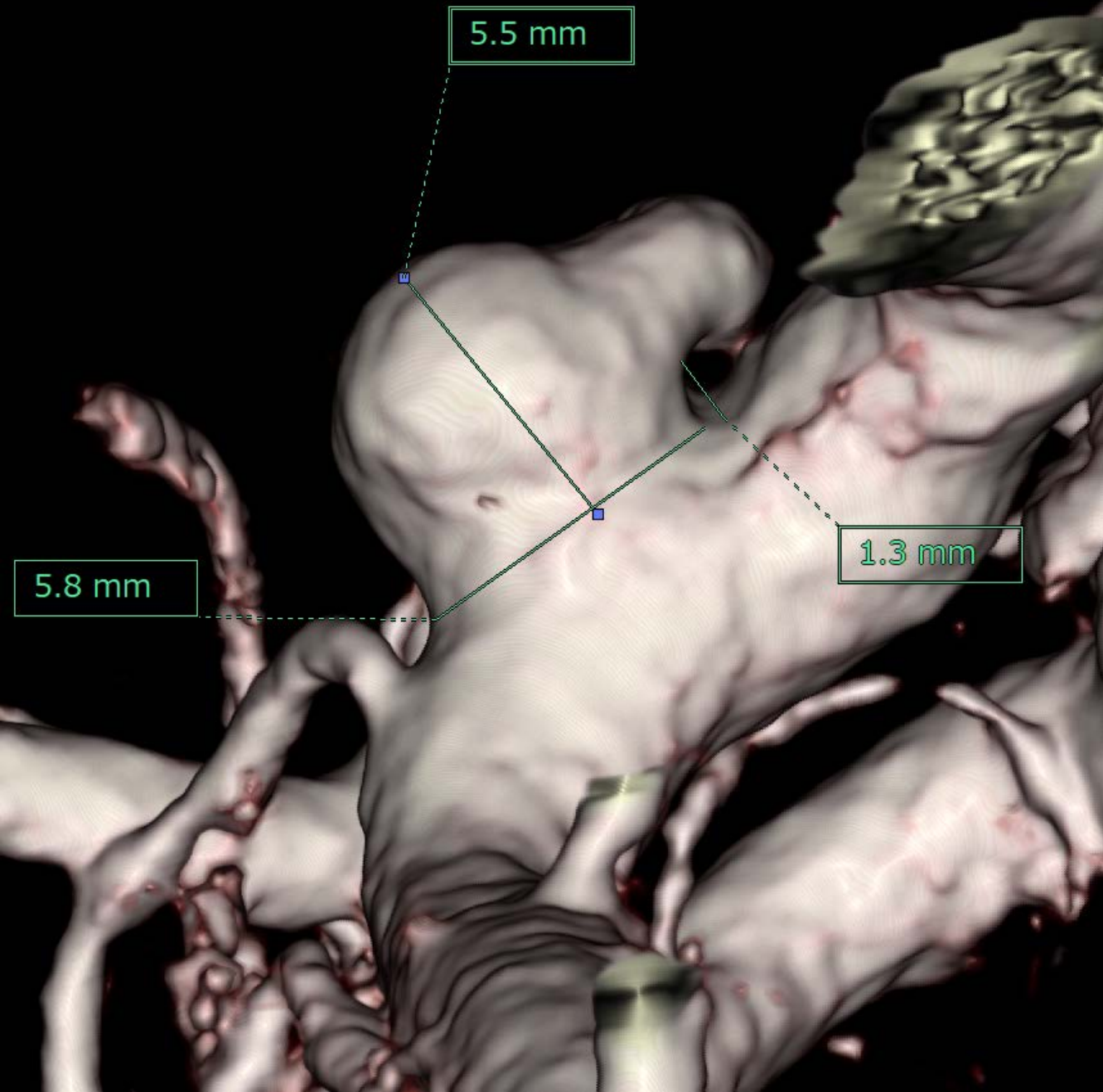




7.0mm UCAS Japan 3.19%/y

RAO:174

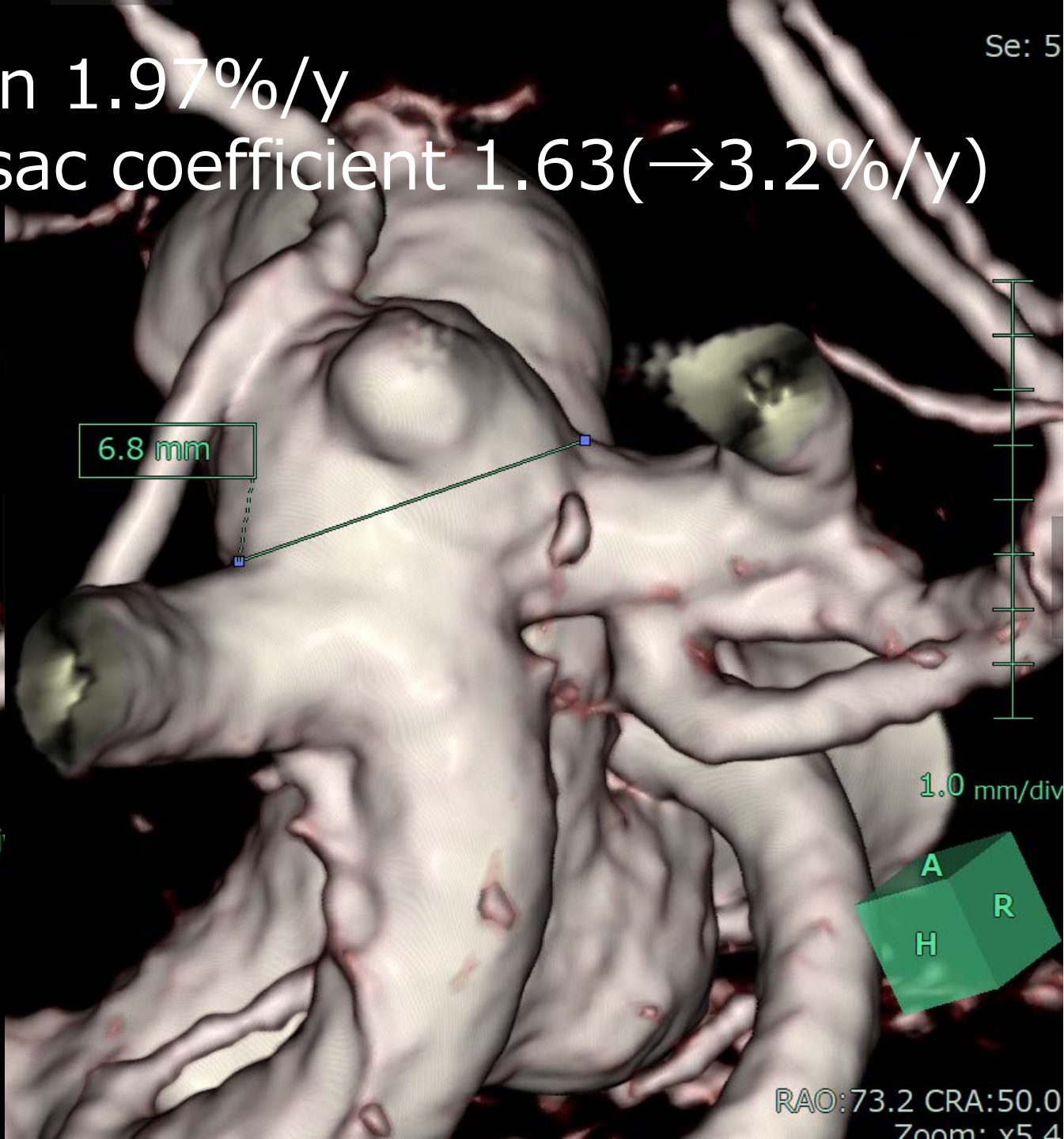
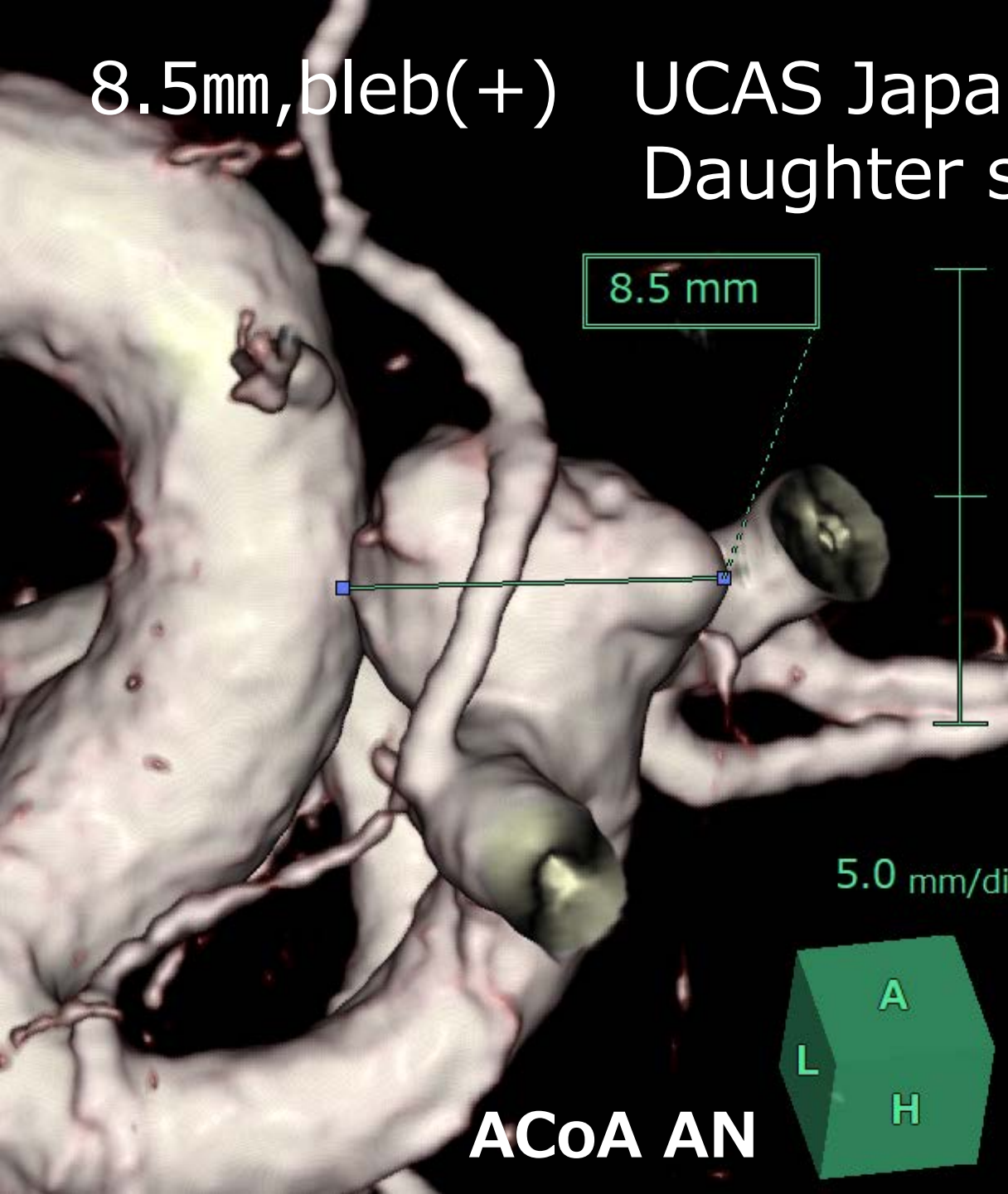# IC-PC AN

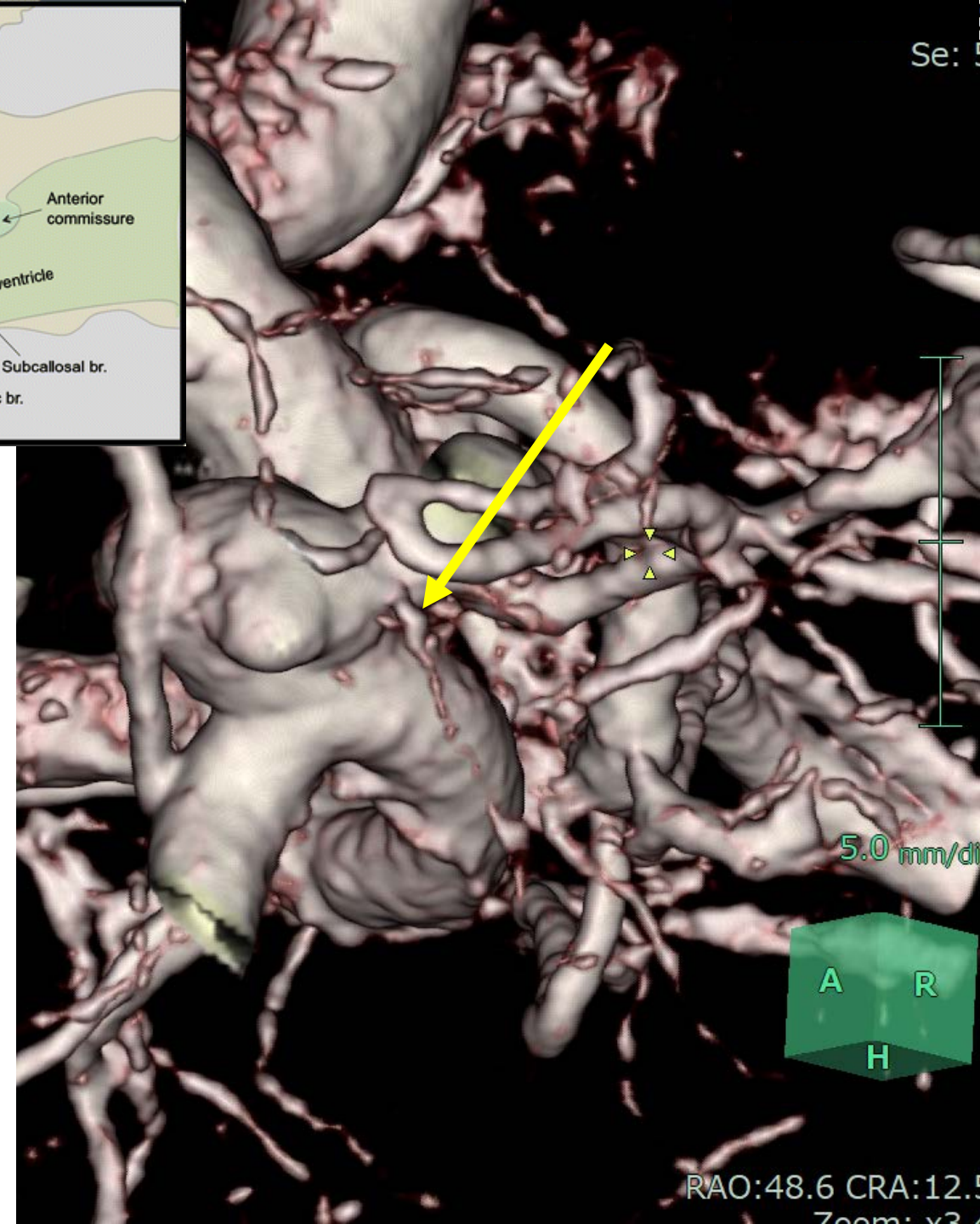
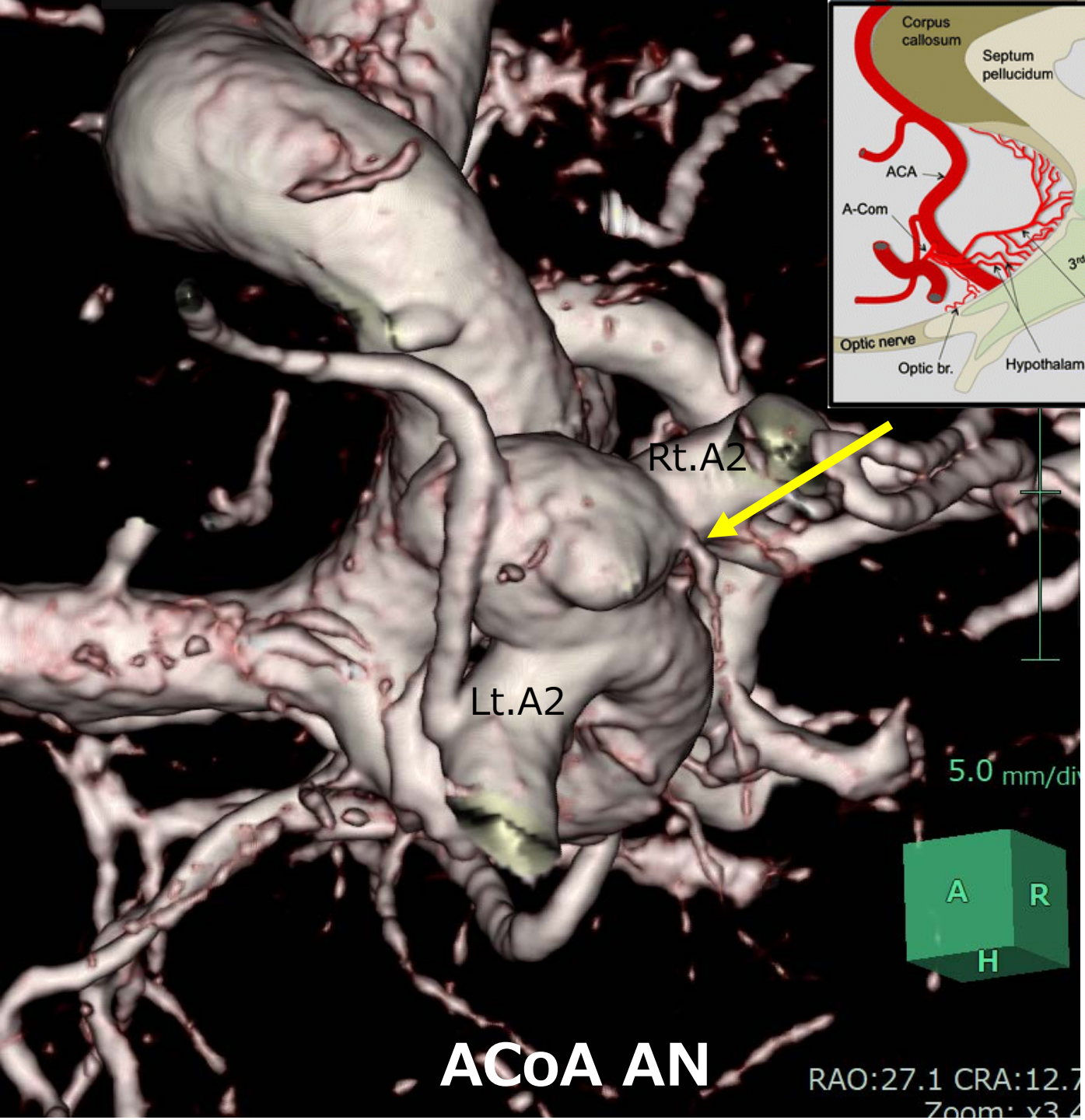


8.5mm, bleb(+)

UCAS Japan 1.97%/y

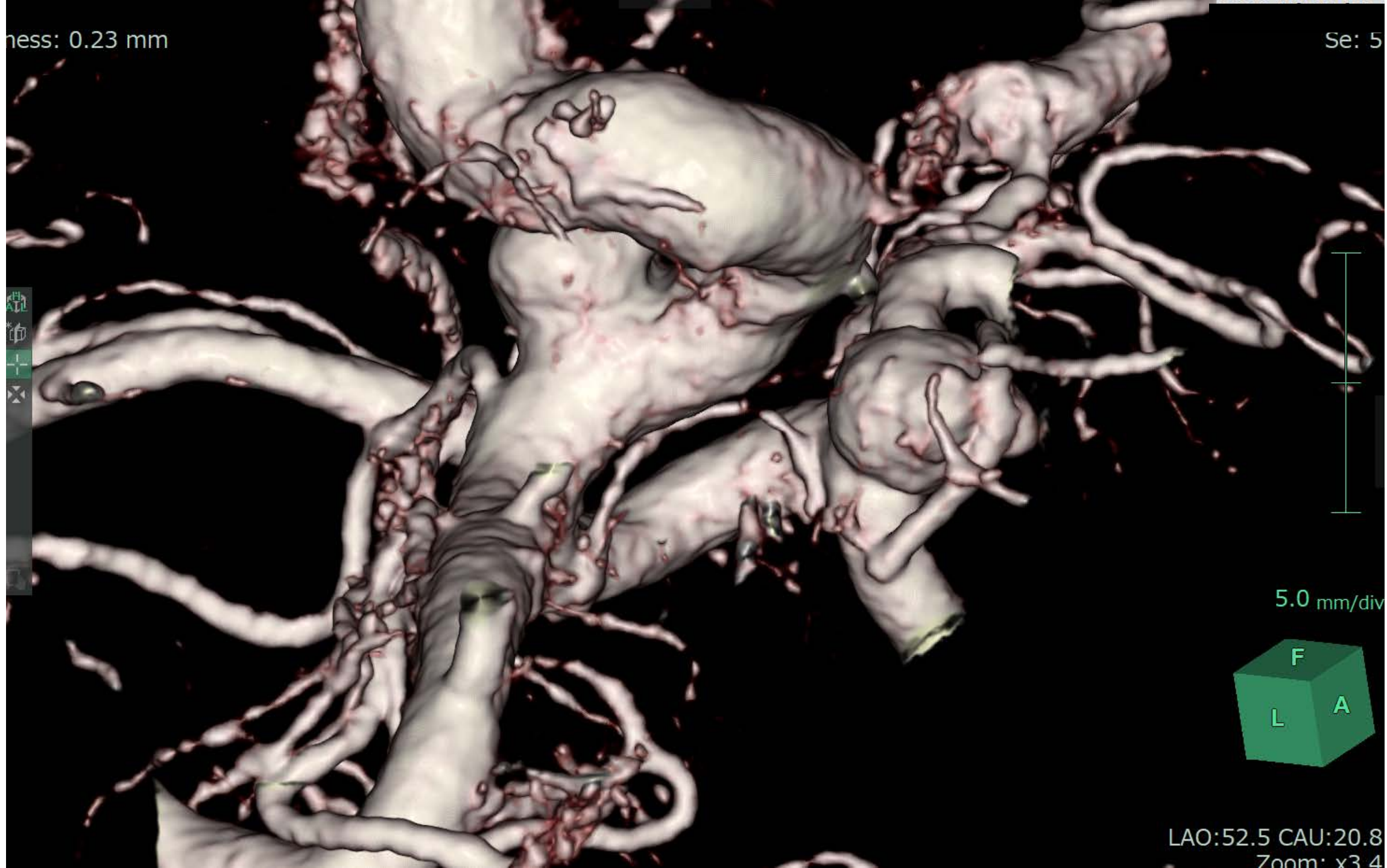
Daughter sac coefficient 1.63(→3.2%/y)



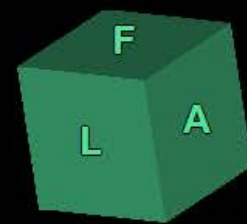


Thickness: 0.23 mm

Se: 5



5.0 mm/div



LAO:52.5 CAU:20.8

Zoom: x3.4